

# Rehabilitation of the Rotator Cuff: An Evaluation-Based Approach

Peter J. Millett, MD, MSc  
Reg B. Wilcox III, PT, DPT, MS  
James D. O'Holleran, MD  
Jon J. P. Warner, MD

Dr. Millett is Assistant Professor of Orthopedics, Harvard Medical School, Boston, MA, and Director of Shoulder Surgery, Steadman Hawkins Clinic, Vail, CO. Dr. Wilcox is Clinical Supervisor, Outpatient Services, Department of Rehabilitation Services, and Fellow, Center for Evidence Based Imaging, Department of Radiology, Brigham and Women's Hospital, Boston. Dr. O'Holleran is Fellow, Harvard Shoulder Service, Brigham and Women's Hospital/Massachusetts General Hospital. Dr. Warner is Professor of Orthopedics, Harvard Medical School, Chief, Harvard Shoulder Service, and Orthopedic Surgeon, Department of Orthopedics, Massachusetts General Hospital.

None of the following authors or the departments with which they are affiliated has received anything of value from or owns stock in a commercial company or institution related directly or indirectly to the subject of this article: Dr. Millett, Dr. Wilcox, Dr. O'Holleran, and Dr. Warner.

Reprint requests: Dr. Millett, Steadman Hawkins Research Foundation, Suite 1000, 181 West Meadow Drive, Vail, CO 81657.

*J Am Acad Orthop Surg* 2006;14:599-609

Copyright 2006 by the American Academy of Orthopaedic Surgeons.

## Abstract

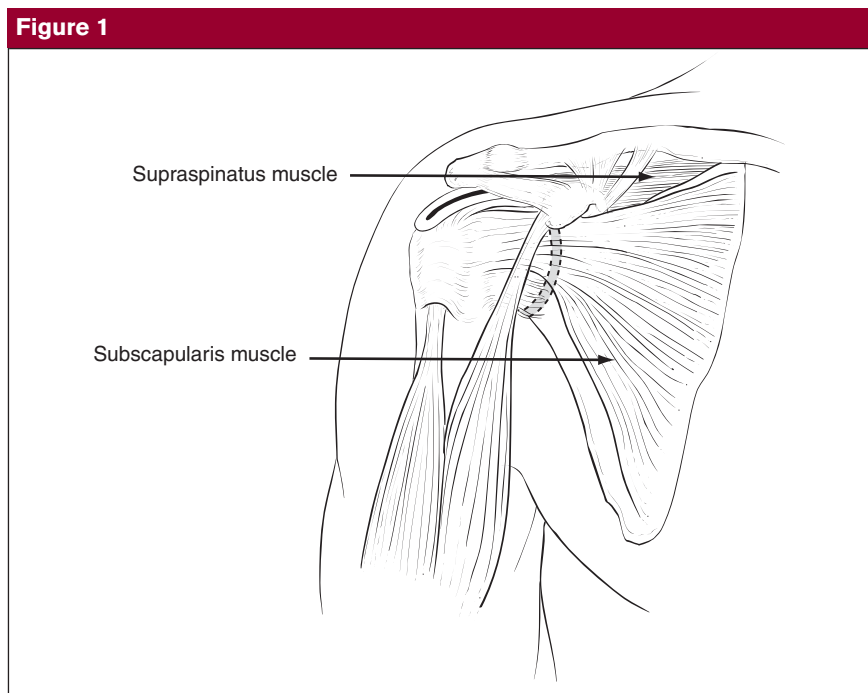
Rotator cuff disease of the shoulder, a common condition, is often incapacitating. Whether nonsurgical or surgical, successful management of rotator cuff disease is dependent on appropriate rehabilitation. Numerous rehabilitation protocols for the management of rotator cuff disease are based primarily on anecdotal clinical observation. The available literature on shoulder rehabilitation, in conjunction with clinical observation that takes into consideration the underlying tissue quality and structural integrity of the rotator cuff, can be compiled into a set of rehabilitation guidelines. The four phases of rehabilitation begin with maintaining and protecting the repair in the immediate postoperative period, followed by progression from early passive range of motion through return to preoperative levels of function.

Rotator cuff tear, a common condition, can manifest clinically in a variety of ways, causing an array of impairment and resultant arm and shoulder dysfunction. Surgery is often done for the painful rotator cuff tear that has failed nonsurgical management. The biomechanical strength of the repaired rotator cuff tendon depends on tissue quality, surgical technique, and materials used.<sup>1-4</sup> Postoperative outcomes for rotator cuff repair are generally good. Increased postoperative strength and decreased pain have been correlated with early surgical repair.<sup>5,6</sup> Typically, patients with smaller tears have better clinical outcomes.<sup>7,8</sup>

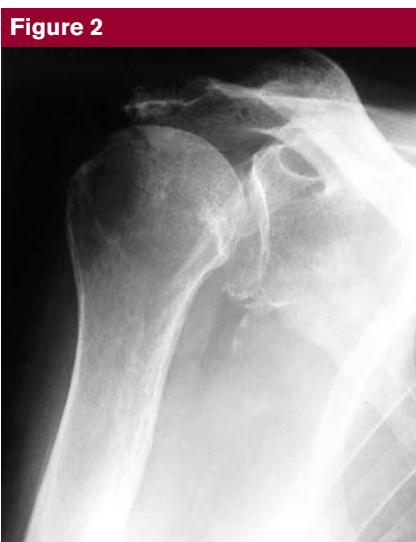Rehabilitation of the rotator cuff is a challenge for the practicing orthopaedic surgeon and physical therapist. Successful management of a rotator cuff tear is often dependent on the specific surgical intervention as well as appropriately planned and executed rehabilitation. Several vari-

ables affect the functional outcome of patients who have undergone rotator cuff repair, including patient age, activity level, duration of symptoms, extent of the tear, location of the tear, number of tendons involved, rotator cuff tissue quality, muscle atrophy, and associated shoulder pathology.

Many current rehabilitation protocols for nonsurgical and postoperative management are based on empirical clinical experience. These protocols indicate a specific exercise/activity progression based on healing time lines. An evaluation-based protocol<sup>9</sup> takes into account not only healing time lines but also the attainment of specific clinical goals. Patients who have undergone rotator cuff repair do not progress in their rehabilitation at the same rate. Clinicians must consider anatomy and biomechanics, underlying pathophysiology, principles of tendon healing, and the specific attributes



Anterior view of the muscles of the rotator cuff. (Reproduced from Wirth MA, Orfaly RM, Rockwood CA Jr: Rotator cuff tear, in Greene WB (ed): *Essentials of Musculoskeletal Care*, ed 2. Rosemont, IL: American Academy of Orthopaedic Surgeons, 2001, p 141.)



Neutral anteroposterior radiograph of a shoulder with a chronic massive rotator cuff tear. There is reduction of the acromiohumeral space, and the humeral head is elevated relative to the glenoid. (Reproduced from Green A: Chronic massive rotator cuff tears: Evaluation and management. *J Am Acad Orthop Surg* 2003;11:321-331.)

and limitations of selected treatment interventions to appropriately adjust the postoperative course of rehabilitation of each patient.

**Basic Science**

**Anatomy and Biomechanics**

The rotator cuff stabilizes the glenohumeral joint and acts to depress and compress the humeral head within the glenoid concavity (Figure 1). Rotator cuff dysfunction, therefore, may result in superior elevation of the humeral head with impingement on the undersurface of the acromion (Figure 2). In some patients with a completely torn rotator cuff, dynamic stability of the humeral head can be preserved because of the interlocking and crossover of the fibers of the rotator cuff tendons. The ultra-histologic arrangement of the rotator cuff tendon fibers is composed of at least four interlocking

layers.<sup>10</sup> These interlocking layers connect the subscapularis with the supraspinatus muscle as they course over the humeral head, thereby allowing the subscapularis to depress the humeral head in some shoulders with a supraspinatus tear.

Cadaveric models have maintained normal humeral translations even with massive supraspinatus tears (up to 5 cm) as long as the infraspinatus, teres minor, and subscapularis muscles remain intact.<sup>11</sup> There is protective overlap in function in the shoulder. Because of the force vector applied by the infraspinatus and subscapularis muscle-tendon units, they contribute to humeral head depression more than does the supraspinatus.<sup>12</sup> Furthermore, the latissimus dorsi and teres major also can effectively depress the head of the humerus.<sup>12</sup> To maximize function, the medical team can incorporate this redundancy in function in a comprehensive should-

er rehabilitation program.

The long head of the biceps tendon is intimately associated with the rotator cuff. Although its specific function remains controversial, the mechanical properties of the long head of the biceps tendon are well known, having been established through the determination of cross-sectional area, ultimate tensile strength, ultimate strain, and strain energy density. The stiffness of the biceps tendon indicates that it has the ability to endure the large loads that could be applied through its muscle belly and thus potentially act as a humeral head depressor. Other studies suggest that the biceps tendon plays a role in anterior shoulder stability by increasing shoulder resistance to torsional forces.<sup>13</sup> Clinical experience, however, indicates that biceps tenotomy and tenodesis have resulted in little functional disability. Even so, the biceps tendon can be a major source of pain and

commonly is injured in rotator cuff tear.

The scapulothoracic articulation also affects rotator cuff function. Kibler and McMullen<sup>14</sup> described scapular dyskinesis, which frequently is seen in association with rotator cuff disease. The patient with a rotator cuff tear presents with either primary or compensatory impairment of the scapular stabilizing musculature, which leads to subtle winging or abnormal kinematics (ie, dyskinesis). This can alter the orientation of the acromial arch and lead to rotator cuff dysfunction. Management of scapular dyskinesis should focus on restoration of normal scapular musculature recruitment patterns.

Abnormalities of the acromioclavicular joint also can lead to rotator cuff dysfunction—either directly, from compression, or indirectly, from pain-induced inhibition. The subacromial bursa, which envelops the proximal humerus and facilitates gliding of the proximal humerus under the coracoacromial arch, contains free nerve endings, Ruffini endings, Pacini corpuscles, and two kinds of unclassified nerve endings.<sup>15</sup> The bursa is thought to contribute to pain; it has a richer supply of free nerve fibers than is found in the rotator cuff tendons, biceps tendon, tendon sheaths, and transverse humeral ligament.<sup>16</sup> The presence of these receptors lends support to the idea that the bursa receives nociceptive and proprioceptive stimuli. In some instances, as the result of adhesions of the subacromial bursa, the bursa may create a mechanical impingement between the acromion and the insertion of the rotator cuff.<sup>17</sup>

### Pathophysiology

The rotator cuff tendons are specialized viscoelastic structures that, because of their collagen configuration, tolerate tremendous tensile stresses (up to 100 N/mm). Compressive and shear forces are poorly

tolerated, however. One hypothesis on the origin of rotator cuff tears suggests that differential strain within the supraspinatus tendon at the articular side and the bursal side leads to shear forces within the tendon that exceed its mechanical strength. The resulting intratendinous microtears then propagate and become larger macroscopic tears. In cadaveric shoulders, a maximum differential strain was reached at approximately 120° of abduction.<sup>18</sup> Partial tears may create tension overload in the remaining tendon, promoting force concentration in the remaining tendon tissue. With time, this leads to complete full-thickness rotator cuff failure.

Degeneration (tendinopathy) and overuse with repetitive extrinsic compression or eccentric overload also may contribute to rotator cuff tendon rupture.<sup>19</sup> Tendinopathy, a noninflammatory degenerative disruption of tendon architecture, results in loss of structural properties and is invariably present in rotator cuff tear. Complete tendon failure occurs from either cumulative attrition (eg, atraumatic tear) or a sudden force that exceeds the structural integrity of the already damaged tissue (eg, traumatic tear).

### Tendon Healing

The potential for spontaneous tendon healing in the rotator cuff has not been established. In most instances, structurally significant healing occurs only with surgical repair of the rotator cuff tendon back to its footprint on the greater and lesser tuberosities of the humerus. Healing principally occurs to the bone, although the bursa may have some intrinsic healing capabilities.

Tendon healing typically is divided into three phases. The inflammatory phase occurs during the first 7 days, when platelets from blood plasma enter the tear to initiate clot formation. Fibrin and fibronectin form cross-links with collagen fi-

bers to form a fragile bond, which helps reduce hemorrhage. Chemotactic mediators attract inflammatory white blood cells, including polymorphonuclear leukocytes and monocytes. The release of histamine and bradykinin increases vascular permeability.

The inflammatory phase gradually transforms into the proliferative phase, which occurs 2 to 3 weeks after tendon injury or repair. Fibroblasts, myofibroblasts, and endothelial cells, which substitute for the acute inflammatory mediators, combine with capillary buds and nascent extracellular matrix to form granulation tissue. This tissue replaces the original fibrin clot with the scaffolding of a more permanent repair tissue. Fibroblasts initially produce type III collagen, which is arranged haphazardly in the absence of cross-linking, and glycosaminoglycans. During the following week, this repair tissue grows stronger during the transition to the maturation phase.

The maturation and remodeling phase begins around week 3 after injury or repair as synthetic activity slowly tapers and scar tissue organizes. Immature type III collagen is replaced by mature type I collagen; the latter aligns along tensile forces. The collagen is continually remodeled until permanent repair tissue is formed. Animal models have shown temporal variation during the maturation phase. Some studies suggest that tendon healing takes 12 to 16 weeks to reach final tensile strength, but others have demonstrated incomplete closure of repaired defects and inadequate mechanical properties in an equivalent time frame.<sup>20,21</sup> In a sheep model, repaired tendons returned to maximal failure loads after only 26 weeks of healing.<sup>21</sup>

### Immobilization

Aggressive early motion that stresses the repair and exceeds the mechanical strength of the repair construct should be avoided. Some

surgeons think that, compared with a traditional sling, an abduction immobilizer better maximizes rotator cuff healing while minimizing rotator cuff repair tension during the early postoperative period. This belief is based on evidence from studies in comparative animal models. Nevertheless, it is clear that proper positioning of the arm during the early healing phases is important. The hypovascular zone of the intact normal supraspinatus is located approximately 1.5 cm from the greater tuberosity.<sup>22</sup> Humeral head position has been shown to have an impact on blood flow. Rathbun and Macnab<sup>23</sup> demonstrated hypovascularity of the supraspinatus with the arm adducted at the side. In sheep models, postoperative immobilization has been shown to reduce tension overload of the repaired cuff.<sup>24</sup> In a rodent model of rotator cuff repair, supraspinatus tendons from rats that were immobilized had markedly higher collagen orientation, more nearly normal extracellular matrix genes, and increased quasilinear viscoelastic properties than did the tendons from subjects that were exercised.<sup>2</sup>

Based on these studies, it seems prudent to recommend that the shoulder be immobilized with an abduction-type immobilizer for the first 4 to 6 weeks after surgery. Patient compliance should be considered when selecting an immobilizer. Some patients find abduction immobilization cumbersome, while others might find it appealing because it provides more support and protection to the operated upper extremity. We suggest immobilizing the arm in slight abduction (45° to 60°) to promote better blood flow to the supraspinatus and minimize tension on the repair.

### Continuous Passive Motion

Passive motion may be initiated as long as the tension on the repair is kept low. Hatakeyama et al<sup>25</sup> report-

ed that the safest resting position after rotator cuff repair is 30° of elevation in the scapular plane, with 0° to 60° of external rotation.

Although the benefits of continuous passive motion (CPM) on cartilage metabolism in other joints have been proved, the benefits of CPM in shoulder rehabilitation remain unproved. Raab et al<sup>26</sup> performed a prospective, randomized, blinded, controlled study on the use of CPM after rotator cuff repair and subacromial decompression in 26 patients. They reported no overall difference in shoulder score at 3 months postoperatively between the group that received physical therapy and the group that received physical therapy plus CPM. However, patients in the physical-therapy-plus-CPM group had greater improvement in range of motion (ROM).<sup>26</sup> The authors reported no structural data about the healing response or integrity of the repaired tendons with CPM.

In their prospective randomized study of 31 patients following rotator cuff repair for tears of various size, Lastayo et al<sup>27</sup> compared two groups. One used CPM for the first 4 postoperative weeks; the other had 4 weeks of supervised passive ROM. At 4 weeks, rehabilitation was the same for both groups. At a mean follow-up of 22 months, there were no differences in validated outcomes measures, visual analog pain scores, overall ROM, and isometric strength. Manual passive ROM by a therapist was more cost effective than using the CPM machine.<sup>27</sup>

In another study, electromyographic analysis was used to measure rotator cuff activity in 10 healthy individuals.<sup>28</sup> No difference in cuff activity level was shown with the use of a CPM machine compared with therapist-assisted passive ROM and Codman's pendulum exercises. Pulley exercises, self-assisted flexion with a bar, and self-assisted internal and external rotation exercises all demonstrated notably higher muscular activity.

### Physical Therapy Modalities

Although commonly used to manage rotator cuff tear, the efficacy of physical therapy modalities such as transcutaneous electrical nerve stimulation, iontophoresis, and ultrasound remains controversial. Few well-controlled clinical trials have evaluated their role in patients with rotator cuff tear. These modalities may have an effect on pain and limited motion, impairment sequelae that are typically present in patients with rotator cuff tear. Their impact on the underlying tear is not known.

### Cryotherapy

Cryotherapy helps control postoperative pain, decreases swelling and muscle spasm, suppresses inflammation, and decreases metabolism. The analgesic effects occur after tissue is cooled to between 50° and 60°F;<sup>29</sup> the depth of cooling is unknown. Most reports of the efficacy of postoperative cryotherapy are based on poorly controlled studies and empirical evidence. However, Speer et al<sup>30</sup> examined the use of cryotherapy in a prospective, randomized, controlled clinical trial. The 25 patients in the cryotherapy group had less pain during the first 24 postoperative hours, with a better potential for sleep and a lesser need for pain medication, than did the 25 patients who did not receive cryotherapy. The subjects who received cryotherapy reported diminished shoulder pain and swelling. Shoulder movement during therapy was less painful by 10 days postoperatively, and these patients were better able to tolerate their rehabilitation.<sup>30</sup>

### Transverse Friction Massage

The role of transverse friction massage in the treatment of tendinitis/tendinosis is primarily based on the soft-tissue work of Cyriax.<sup>31</sup> No scientific data support the use of transverse friction massage.

## Guidelines for Nonsurgical Management

### Impingement and Partial-Thickness Rotator Cuff Tears

Impingement and partial-thickness tears of the rotator cuff usually are treated nonsurgically. The rehabilitation goals include reestablishing full ROM, synchronizing the firing of the rotator cuff and periscapular muscles, and reestablishing normal glenohumeral and scapulothoracic kinematics. This program should be performed in positions that avoid both impingement of the rotator cuff tendons on the overlying acromial arch and further stress on the rotator cuff. Elimination of posterior capsular contractures decreases the obligate antero-superior translation of the shoulder, which minimizes contact between the rotator cuff and the acromion.<sup>32</sup> Appropriate strengthening of the infraspinatus, teres minor, and subscapularis permits the rotator cuff muscles to function in a concerted way to oppose superior humeral head translation and potentially reduce subacromial impingement. Manual physical therapy techniques (eg, joint mobilization) in conjunction with supervised exercise have been shown to be more effective than exercise alone in strength gains, pain reduction, and improved function.<sup>33,34</sup> Because of the lack of sound scientific data regarding the efficacy of ultrasound and iontophoresis, we do not recommend their routine use.

### Full-Thickness Rotator Cuff Tear

Although nonsurgical management of rotator cuff tears can be successful, there are no reliable methods of predicting successful outcomes. Some patients recover function and have minimal or no pain after a rotator cuff tear; others are severely disabled. Electromy-

graphic (EMG) studies have shown that the subscapularis muscle is active in patients who preserve function and compensate for their torn rotator cuff; thus, it seems reasonable to focus a rehabilitation program on this important internal rotator and humeral head depressor.<sup>35</sup> The management goal should be to achieve a balanced, axial plane force couple between the subscapularis muscle anteriorly and the infraspinatus and teres minor muscles posteriorly.

The goals of nonsurgical management of rotator cuff tear are to eliminate pain and restore function. The initial goals are to decrease inflammation and restore motion. Eliminating contractures decreases the risk of subacromial impingement. Once this occurs, rotator cuff strengthening allows the intact and functioning cuff musculature to compensate for the torn tendon or tendons. If nonsurgical management fails, many believe, as we do, that recovery from surgical rotator cuff repair is easier in a shoulder that was supple preoperatively than in one that was stiff.

## Postoperative Management

The goals of rehabilitation after rotator cuff repair are to achieve healing of the cuff while restoring pain-free motion and function. Patient-related factors, such as prior surgery, smoking, and comorbidities, undoubtedly influence tendon healing, rehabilitation, and ultimate clinical outcomes. Each variable should be considered when formulating a postoperative therapy plan, and it is important for surgeons and therapists to recognize that the strength of rotator cuff repairs can vary substantially.<sup>3,4</sup> Ongoing communication and coordination of care between the orthopaedic surgeon and physical therapist should enable optimal functional outcomes.

Initially, the repair is protected

until the healing tissue is strong enough to begin active ROM. With good tissue quality and a strong repair construct, early passive ROM can be advocated in phase 1 of the rehabilitation. The degree of muscle atrophy and fatty degeneration directly correlates with the reparability of the tear;<sup>36</sup> these elements are key predictive factors for the risk of re-tear.<sup>37</sup> In the presence of rotator cuff atrophy, a 25% to 85% chance of re-tearing has been reported;<sup>36</sup> therefore, in all but the smallest tear, the arm should be protected for at least 4 to 6 weeks. The authors prefer to use an abduction sling to minimize tension on the repair.

## Perioperative Management

Whether the repair is performed via arthroscopy or open technique, there are few data on the loads that develop across the repair during the perioperative period. Some experts speculate that the reflexive muscle contraction that occurs in the perioperative period may lead to dangerously high loads on the repair. Therefore, maintenance of muscle paralysis after surgery with regional interscalene block may provide additional protection in the early postoperative period. Better repair techniques permit stronger repairs, which allow motion to commence earlier with less risk of re-rupture. Arthroscopic repairs are thought to be less traumatic to the deltoid muscle and seem to create less scar tissue, thus minimizing the risk of postoperative stiffness.

## Postoperative Rehabilitation

There are four widely used and accepted phases of shoulder rehabilitation (Table 1). Phase 1 involves passive exercises that minimize loads across the repair. Phase 2 consists of active exercises that gradually apply loads to the repair construct and begin to transfer loads back onto the healing tissues. Phase 3 consists of strengthening exercises focused

<b>Table 1</b>	
<b>The Four Phases of Healing During Rehabilitation Following Rotator Cuff Surgery</b>	
<p><b>Phase 1: Immediate postoperative period (weeks 0-6)</b></p> <p><b>Goals</b>                      Maintain/protect integrity of repair                      Gradually increase PROM                      Diminish pain and inflammation                      Prevent muscular inhibition                      Become independent with modified ADLs</p> <p><b>Precautions</b>                      Maintain arm in abduction sling/brace, remove only for exercise                      No shoulder AROM, lifting of objects, shoulder motion behind back, excessive stretching or sudden movements, supporting of any weight, lifting of body weight by hands                      Keep incision clean and dry</p> <p><b>Criteria for progression to phase 2</b>                      Passive forward flexion to <math>\geq 125^\circ</math>                      Passive ER in scapular plane to <math>\geq 75^\circ</math> (if uninvolved shoulder PROM <math>&gt; 80^\circ</math>)                      Passive IR in scapular plane to <math>\geq 75^\circ</math> (if uninvolved shoulder PROM <math>&gt; 80^\circ</math>)                      Passive abduction to <math>\geq 90^\circ</math> in the scapular plane</p> <p><b>Days 1 to 6</b>                      Abduction brace/sling                      Pendulum exercises                      Finger, wrist, and elbow AROM                      Begin scapula musculature isometrics/sets; cervical ROM                      Cryotherapy for pain and inflammation</p> <p><b>Days 1-2</b>                      As much as possible (20 min/h)</p> <p><b>Days 3-6</b>                      Post-activity, or for pain                      Sleep in abduction sling                      Patient education on posture, joint protection, positioning, hygiene</p> <p><b>Days 7-28</b>                      Continue with abduction sling/brace                      Pendulum exercises                      Begin PROM to tolerance (done supine; should be pain free)                          Flexion to <math>90^\circ</math>                          ER in scapular plane to <math>\geq 35^\circ</math>                          IR to body/chest                      Continue elbow, wrist, and finger AROM/resisted                      Cryotherapy as needed for pain control and inflammation                      May resume general conditioning program (eg, walking, stationary bicycle)                      Aquatherapy/pool therapy may begin 3 weeks postoperative</p>	<p><b>Phase 2: Protection and active motion (weeks 6-12)</b></p> <p><b>Goals</b>                      Allow healing of soft tissue                      Do not overstress healing tissue                      Gradually restore full PROM (weeks 4-5)                      Decrease pain and inflammation</p> <p><b>Precautions</b>                      No lifting                      No supporting body weight with hands and arms                      No sudden jerking motions                      No excessive behind the back movements                      Avoid upper extremity bike and ergometer</p> <p><b>Criteria for progression to phase 3</b>                      Full AROM</p> <p><b>Weeks 5-6</b>                      Continue with full-time sling/brace until end of week 4                      Between weeks 4 and 6, use sling/brace for comfort only                      Discontinue sling/brace at end of week 6                      Initiate AAROM flexion in supine position                      Progressive PROM until approximately full ROM at weeks 4-5                          Gentle scapular/glenohumeral joint mobilization as indicated to regain full PROM                      Initiate prone rowing to neutral arm position                      Continue cryotherapy as needed                      May use heat before ROM exercises                      Aquatherapy okay for light AROM exercises                      Ice after exercise</p> <p><b>Weeks 6-8</b>                      Continue AROM, AAROM, and stretching exercises                      Begin rotator cuff isometrics                      Continue periscapular exercises                      Initiate AROM exercises (flexion scapular plane, abduction, ER, IR)</p>
<p>*Patient must be able to elevate arm without shoulder or scapular hiking before initiating isotonic; if unable, continue glenohumeral joint exercises                      AAROM = active-assisted range of motion, ADL = activity of daily living, AROM = active range of motion, ER = external rotation, IR = internal rotation, PROM = passive range of motion, ROM = range of motion</p>	

on restoring power and endurance to the healed rotator cuff muscles. Phase 3 can be further divided into

an additional phase—phase 4, advanced strengthening. Postoperative goals are to mobi-

lize the joint early, load the repaired rotator cuff tendons safely, and strengthen the rotator cuff muscles

**Table 1 (continued)****Phase 3: Early strengthening (weeks 10-16)****Goals**

- Full AROM (weeks 10-12)
- Maintain full PROM
- Dynamic shoulder stability
- Gradual restoration of shoulder strength, power, and endurance
- Optimize neuromuscular control
- Gradual return to functional activities

**Precautions**

- No lifting objects >5 lbs, sudden lifting or pushing activities, sudden jerking motions, overhead lifting
- Avoid upper extremity bike and ergometer

**Criteria for progression to phase 4**

- Ability to tolerate progression to low-level functional activities
- Demonstrated return of strength/dynamic shoulder stability
- Reestablishment of dynamic shoulder stability
- Demonstrated adequate strength and dynamic stability for progression to more demanding work- and sport-specific activities

**Week 10**

- Continue stretching and PROM, as needed
- Dynamic stabilization exercises
- Initiate strengthening program
  - ER and IR with exercise bands/sport cord/tubing
  - ER side-lying (lateral decubitus)
  - Lateral raises\*
  - Full can in scapular plane\* (no empty can abduction exercises)
  - Prone rowing
  - Prone horizontal abduction
  - Prone extension
  - Elbow flexion
  - Elbow extension

**Week 12**

- Continue all exercise listed above
- Initiate light functional activities as permitted

**Week 14**

- Continue all exercise listed above
- Progress to fundamental shoulder exercises

**Phase 4: Advanced strengthening (weeks 16-22)****Goals**

- Maintain full nonpainful AROM
- Advanced conditioning exercises for enhanced functional use
- Improve muscular strength, power, and endurance
- Gradual return to full functional activities

**Week 16**

- Continue ROM and self-capsular stretching for ROM maintenance
- Continue progression of strengthening
- Advance proprioceptive, neuromuscular activities
- Light sports (golf chipping/putting, tennis ground strokes) if doing well

**Week 20**

- Continue strengthening and stretching
- Continue stretching if motion is tight
- Initiate interval sport program (eg, golf, doubles tennis) if appropriate

\*Patient must be able to elevate arm without shoulder or scapular hiking before initiating isotonic; if unable, continue glenohumeral joint exercises

AAROM = active-assisted range of motion, ADL = activity of daily living, AROM = active range of motion, ER = external rotation, IR = internal rotation, PROM = passive range of motion, ROM = range of motion

progressively. Extensive empirical clinical experience exists as to the effectiveness of this rehabilitation

strategy; EMG studies have provided a basic science foundation, as well.<sup>38</sup> Progressive EMG activity and

thus, loading, has been demonstrated in individuals who moved through the first three phases of

shoulder rehabilitation. Passive ROM exercises performed in the supine position showed the least EMG activity, whereas strengthening exercises showed the highest levels of EMG activity in the deltoid and rotator cuff musculature.

### **Phase 1: Passive Range of Motion (0 to 6 weeks)**

During the first 2 to 4 weeks after tendon repair, loads across the repair site must be minimal. The weak fibrin clot gives way to a loosely organized type III collagen callus, neither of which can withstand physiologic loads. The gradual introduction of tensile stress during the maturation process may assist in the proper orientation of mature type I collagen fibers. Numerous clinical series have described the benefit of early passive motion. The type of motion employed in the early rehabilitation period is crucial to ensure proper tendon gliding and healing, but no clear guidelines exist. Passive ROM exercises should be performed within a safe (ie, low load) ROM. Pressure at the end of the range (stretching) should be avoided for the first 6 weeks. We do not recommend the use of pulleys or self-assisted motion; EMG studies have shown that the rotator cuff is not “quiet” with such activities, so true passive ROM is not accomplished.<sup>28</sup>

Excessive adduction or internal rotation is avoided because these may place excessive stress on the repair. We recommend immobilizing the arm in slight abduction (30° to 45°) during this phase for two reasons. First, this position may enhance regional blood flow by preventing the “wringing out” effect in blood vessels to the tendon. Second, abduction shortens the distance between the origin and the insertion of the muscle tendon unit so that passive tension on the repair site will be decreased.

Aquatherapy can be a useful adjunct once the surgical incisions have healed. From weeks 2 to 6, gen-

tle stretching and passive motion can be performed in a pool, 2 to 3 days per week, for 15 to 20 minutes per session. At 6 to 8 weeks postoperatively, aquatherapy can usually be advanced with the addition of active motion. In our experience, at 10 to 12 weeks the patient can do underwater resistance exercises. Aquatherapy is considered to be active-assisted ROM in a gravity-reduced environment and likely places load across the repair. To our knowledge, this has never been quantified. It has been shown that shoulder elevation in the water results in a markedly lower activation of the rotator cuff compared with dry land exercise.<sup>39</sup> This decreased muscle activation during exercise in water should allow for earlier active motion in the postoperative period without compromising the integrity of the repair.

Based on the best scientific data available, we recommend the following during phase 1: use of an abduction pillow shoulder immobilizer for 6 weeks (4 weeks for incomplete or small rotator cuff tendon tears), immediate passive ROM (depending on observed tension on tendon repair during surgery and the security of the repair construct), aquatherapy (beginning at 2 to 4 weeks for strong, securely repaired tendon tears), pendulum exercises, and cryotherapy.

### **Phase 2: Active Range of Motion (6 to 12 weeks)**

By 6 weeks postoperatively, tendon healing to bone is sufficient to withstand applied muscle forces generated by simply raising the arm. This low-level loading will likely increase muscle activity and restore normal patterns of muscle contraction that will enable activities of daily living. The scapulothoracic articulation also should be a focus of therapy. Resistance work is not yet permitted because tendon-to-bone healing strength is insufficient for the forces generated during strength-

ening. The use of pulleys, active-assisted ROM, and self-assisted ROM are appropriate at this point. Strengthening should be avoided. Overly aggressive strengthening at this stage can result in a re-tear, likely the result of suture cutout or tendon failure. We recommend the following in phase 2: continued passive ROM; introduction of active-assisted ROM; gradual introduction of active ROM; use of the arm for activities of daily living; ongoing aquatherapy; and patient-directed, self-assisted therapy using overhead pulley and stick-assistance methods.

### **Phase 3: Strengthening (10 to 16 weeks)**

The strengthening phase should begin approximately 10 to 12 weeks postoperatively. Animal studies and empirical clinical observation indicate that, by this time, tendon-to-bone healing generally is strong enough to allow a gradual program of muscle strengthening. Glenohumeral and scapulothoracic kinematics, as well as soft-tissue compliance, should be sufficiently restored so that a strengthening program can be safely initiated without irritating the shoulder. Attempts to strengthen a stiff shoulder can cause pain, subacromial impingement, and excessive stress on the repair.

Isometric exercises safely permit the controlled application of forces across the tendons. These exercises usually are safe to start early for the periscapular muscles, deltoid, and trapezius because they do not stress the injured or repaired tendons. However, it is unclear whether these muscles can be activated independently in the postoperative patient. Based on the results of their EMG study, Jenp et al<sup>40</sup> concluded that neutral to mid-rotational positions in the scapular plane at 90° of elevation best isolate the supraspinatus, whereas a half externally rotated position in 90° of elevation best isolates the infraspinatus and teres minor muscles.



Subacromial contact can occur when the shoulder is positioned overhead. Such contact may exacerbate impingement or stress the repair. Thus, initial exercising of the internal and external rotators should be performed with the arm below the level of the shoulder. We do not recommend the use of overhead strengthening or upper extremity bicycles or ergometers because these devices place the shoulder in positions that promote mechanical impingement.

The second phase of strengthening begins with elastic resistance exercises, concentrating on high repetitions with moderate resistance. The goal of these exercises is to build muscle endurance. The four key exercises are external rotation (infraspinatus, teres minor), internal rotation (subscapularis), forward flexion (anterior deltoid, supraspinatus), and rowing motion (posterior deltoid, periscapular muscles). More advanced exercises are added as tolerated. Gradual progression of shoulder elevation may be needed along with internal rotation strengthening exercises. Once shoulder mobility is maintained, advanced strengthening exercises are permitted to increase muscular load.

Both empty can (internal rotation, or thumb down) and full can (external rotation, or thumb up) abduction in the plane of the scapula are effective exercises for supraspinatus strengthening.<sup>41</sup> Magnetic resonance imaging (MRI) studies, however, have shown that the subacromial space is reduced with the combination of abduction and internal rotation.<sup>42</sup> Horrigan et al<sup>43</sup> used MRI to assess three exercises for rotator cuff rehabilitation: scaption (abduction in the plane of the scapula) with internal rotation (empty can), military press, and side-lying abduction to 45°. All of the exercises demonstrated an increase in signal intensity in the muscles studied with the exception of the teres minor, which showed no significant

increase in signal intensity with any exercise. Side-lying abduction showed the greatest signal increase in the supraspinatus, subscapularis, infraspinatus, and deltoid muscles. Scaption with internal rotation showed the second highest signal increase in the supraspinatus, subscapularis, and infraspinatus, and the greatest increase in the trapezius.<sup>43</sup> There is greater risk of impingement with scaption with internal rotation; thus, side-lying abduction to 45° may more effectively recruit the supraspinatus with less risk of impingement during the early phases of postoperative rehabilitation.

Based on these data, we do not recommend empty can abduction exercises. Any exercise that causes pain, stiffness, or swelling should be discontinued. The periscapular muscles and deltoid (anterior and posterior) muscles always should be included as part of a comprehensive program to restore strength and kinematics. A core strengthening program also is encouraged.

We recommend continued passive ROM exercises and stretching, progressive strengthening (both concentric and eccentric, using safe motions), and advanced proprioceptive and neuromuscular activities in preparation for light sports activity (eg, golf chipping/putting, tennis ground strokes) as tolerated.

#### **Phase 4: Advanced Strengthening (16 to 22 weeks)**

Phase 4, the advanced strengthening phase, is a progression of phase 3 and serves as a transition to sport-specific rehabilitation activities. After successful completion of the earlier phases of rehabilitation, a gradual return to sports and recreation activities is recommended. Rehabilitation guidelines that simulate sports and recreational activities, commonly referred to as interval sport programs, are intended to safely return an athlete to competition as soon as possible while progres-

sively applying appropriate forces to healing structures. Patients who are not athletes benefit from a functional progression that simulates activities of daily living and work-specific activity.

### **Summary**

Rehabilitation of the injured rotator cuff is a common challenge to the practicing orthopaedic surgeon, physical therapist, and patient. Communication and coordination of care are essential to optimize outcomes, as is appropriate therapy in both nonsurgical and surgical management of rotator cuff disorders. Whether surgical or nonsurgical, the goals of shoulder rehabilitation are to reestablish full, symmetric passive and active motion, balance the force couples in the coronal and axial planes, and restore pain-free shoulder motion and function.

Many factors influence surgical decision-making and technique, which in turn influence the stability of the repair and the ultimate outcome. Clear communication with the patient and the treating therapist helps optimize the overall outcome. Treatment is individualized according to patient age and expectations, tear size, chronicity and tissue quality, and security of the repair. A rational approach focuses on early and safe motion as the tendons are healing. The key is to maintain joint mobility while avoiding excessive stress on the repair.

Basic science evidence supports immobilization in the appropriate position of abduction as well as the use of cryotherapy during the early postoperative stages. Early passive ROM is advocated when the repair is secure. Once passive ROM is established and the repair has had time to heal, active ROM commences. This progressively loads the rotator cuff repair. Aquatherapy, which minimizes the effects of gravity, can be a helpful adjunct at this stage. When the repair is sufficiently strong (10 to

12 weeks), strengthening begins with elastic resistance exercises. Concentric and eccentric loading patterns are appropriate. For a typical supraspinatus tendon repair, scaption with internal rotation (empty can) exercises should be avoided. At 3 to 4 months postoperatively, sport-specific rehabilitation should commence, as tolerated. For the nonathlete, rehabilitation is focused on activities of daily living and work-specific tasks.

## References

Citation numbers printed in **bold type** indicate references published within the past 5 years.

*Evidence-based Medicine*: Level I or II prospective randomized studies include references 6, 26, 27, and 33. The remaining references are anatomic or biomechanical studies, case-controlled studies, or expert opinion.

1. Battaglia TC, Clark RT, Chhabra A, Gaschen V, Hunziker EB, Mikic B: Ultrastructural determinants of murine achilles tendon strength during healing. *Connect Tissue Res* 2003;44:218-224.
2. Thomopoulos S, Williams GR, Soslowsky LJ: Tendon to bone healing: Differences in biomechanical, structural, and compositional properties due to a range of activity levels. *J Biomech Eng* 2003;125:106-113.
3. Gerber C, Schneeberger AG, Beck M, Schlegel U: Mechanical strength of repairs of the rotator cuff. *J Bone Joint Surg Br* 1994;76:371-380.
4. Burkhart SS, Danaceau SM, Pearce CE Jr: Arthroscopic rotator cuff repair: Analysis of results by tear size and by repair technique-margin convergence versus direct tendon-to-bone repair. *Arthroscopy* 2001;17:905-912.
5. Bassett RW, Cofield RH: Acute tears of the rotator cuff: The timing of surgical repair. *Clin Orthop Relat Res* 1983;175:18-24.
6. Cofield RH, Parvizi J, Hoffmeyer PJ, Lanzer WL, Ilstrup DM, Rowland CM: Surgical repair of chronic rotator cuff tears: A prospective long-term study. *J Bone Joint Surg Am* 2001;83:71-77.
7. Bjorkenheim JM, Paavolainen P, Ahovuo J, Slatits P: Surgical repair of the rotator cuff and surrounding tissues: Factors influencing the results. *Clin Orthop Relat Res* 1988;236:148-153.
8. Hawkins RJ, Misamore GW, Hobeika PE: Surgery for full-thickness rotator-cuff tears. *J Bone Joint Surg Am* 1985;67:1349-1355.
9. Noyes FR, DeMaio M, Mangine RE: Evaluation-based protocols: A new approach to rehabilitation. *Orthopedics* 1991;14:1383-1385.
10. Cooper DE, O'Brien SJ, Warren RF: Supporting layers of the glenohumeral joint: An anatomic study. *Clin Orthop Relat Res* 1993;289:144-155.
11. Thompson WO, Debski RE, Boardman ND III, et al: A biomechanical analysis of rotator cuff deficiency in a cadaveric model. *Am J Sports Med* 1996;24:286-292.
12. Halder AM, Zhao KD, O'Driscoll SW, Morrey BF, An KN: Dynamic contributions to superior shoulder stability. *J Orthop Res* 2001;19:206-212.
13. McGough RL, Debski RE, Taskiran E, Fu FH, Woo SL: Mechanical properties of the long head of the biceps tendon. *Knee Surg Sports Traumatol Arthrosc* 1996;3:226-229.
14. Kibler WB, McMullen J: Scapular dyskinesis and its relation to shoulder pain. *J Am Acad Orthop Surg* 2003;11:142-151.
15. Ide K, Shirai Y, Ito H, Ito H: Sensory nerve supply in the human subacromial bursa. *J Shoulder Elbow Surg* 1996;5:371-382.
16. Soifer TB, Levy HJ, Soifer FM, Kleinbart F, Vigorita V, Bryk E: Neurohistology of the subacromial space. *Arthroscopy* 1996;12:182-186.
17. Machida A, Sugamoto K, Miyamoto T, Inui H, Watanabe T, Yoshikawa H: Adhesion of the subacromial bursa may cause subacromial impingement in patients with rotator cuff tears: Pressure measurements in 18 patients. *Acta Orthop Scand* 2004;75:109-113.
18. Reilly P, Amis AA, Wallace AL, Emery RJ: Supraspinatus tears: Propagation and strain alteration. *J Shoulder Elbow Surg* 2003;12:134-138.
19. Soslowsky LJ, Thomopoulos S, Esmail A, et al: Rotator cuff tendinosis in an animal model: Role of extrinsic and overuse factors. *Ann Biomed Eng* 2002;30:1057-1063.
20. Carpenter JE, Thomopoulos S, Flanagan CL, DeBano CM, Soslowsky LJ: Rotator cuff defect healing: A biomechanical and histologic analysis in an animal model. *J Shoulder Elbow Surg* 1998;7:599-605.
21. Lewis CW, Schlegel TF, Hawkins RJ, James SP, Turner AS: The effect of mobilization on rotator cuff healing using modified Mason-Allen stitches: A biomechanical study in sheep. *Biomed Sci Instrum* 2001;37:263-268.
22. Determe D, Rongieres M, Kany J, et al: Anatomic study of the tendinous rotator cuff of the shoulder. *Surg Radiol Anat* 1996;18:195-200.
23. Rathbun JB, Macnab I: The microvascular pattern of the rotator cuff. *J Bone Joint Surg Br* 1970;52:540-553.
24. Gerber C, Schneeberger AG, Perren SM, Nyffeler RW: Experimental rotator cuff repair: A preliminary study. *J Bone Joint Surg Am* 1999;81:1281-1290.
25. Hatakeyama Y, Itoi E, Pradhan RL, Urayama M, Sato K: Effect of arm elevation and rotation on the strain in the repaired rotator cuff tendon: A cadaveric study. *Am J Sports Med* 2001;29:788-794.
26. Raab MG, Rzeszutko D, O'Connor W, Greatting MD: Early results of continuous passive motion after rotator cuff repair: A prospective, randomized, blinded, controlled study. *Am J Orthop* 1996;25:214-220.
27. Lastayo PC, Wright T, Jaffe R, Hartzel J: Continuous passive motion after repair of the rotator cuff: A prospective outcome study. *J Bone Joint Surg Am* 1998;80:1002-1011.
28. Dockery ML, Wright TW, LaStayo PC: Electromyography of the shoulder: An analysis of passive modes of exercise. *Orthopedics* 1998;21:1181-1184.
29. O'Brien SJ, Warren RF, Schwartz E: Anterior shoulder instability. *Orthop Clin North Am* 1987;18:395-408.
30. Speer KP, Warren RF, Horowitz L: The efficacy of cryotherapy in the postoperative shoulder. *J Shoulder Elbow Surg* 1996;5:62-68.
31. Cyriax PJ: *Textbook of Orthopaedic Medicine: Vol 1. Diagnosis of Soft Tissue Lesions*, ed 8. London, England: Bailliere Tindall, 1982.
32. Goldberg BA, Scarlat MM, Harryman DT II: Management of the stiff shoulder. *J Orthop Sci* 1999;4:462-471.
33. Bang MD, Deyle GD: Comparison of supervised exercise with and without manual physical therapy for patients with shoulder impingement syndrome. *J Orthop Sports Phys Ther* 2000;30:126-137.
34. Conroy DE, Hayes KW: The effect of joint mobilization as a component of comprehensive treatment for primary shoulder impingement syndrome. *J Orthop Sports Phys Ther* 1998;28:3-14.

35. Kelly BT, Kirkendall DT, Levy AS, Speer KP: Current research on muscle activity about the shoulder. *Instr Course Lect* 1997;46:53-66.
36. Thomazeau H, Boukobza E, Morcet N, Chaperon J, Langlais F: Prediction of rotator cuff repair results by magnetic resonance imaging. *Clin Orthop Relat Res* 1997;344:275-283.
37. Schaefer O, Winterer J, Lohrmann C, Laubenberger J, Reichelt A, Langer M: Magnetic resonance imaging for supraspinatus muscle atrophy after cuff repair. *Clin Orthop Relat Res* 2002;403:93-99.
38. McCann PD, Wootten ME, Kadaba MP, Bigliani LU: A kinematic and electromyographic study of shoulder rehabilitation exercises. *Clin Orthop Relat Res* 1993;288:179-188.
39. Kelly BT, Roskin LA, Kirkendall DT, Speer KP: Shoulder muscle activation during aquatic and dry land exercises in nonimpaired subjects. *J Orthop Sports Phys Ther* 2000;30:204-210.
40. Jenp YN, Malanga GA, Growney ES, An KN: Activation of the rotator cuff in generating isometric shoulder rotation torque. *Am J Sports Med* 1996;24:477-485.
41. Takeda Y, Kashiwaguchi S, Endo K, Matsuura T, Sasa T: The most effective exercise for strengthening the supraspinatus muscle: Evaluation by magnetic resonance imaging. *Am J Sports Med* 2002;30:374-381.
42. Graichen H, Bonel H, Stammberger T, Englmeier KH, Reiser M, Eckstein F: Subacromial space width changes during abduction and rotation: A 3-D MR imaging study. *Surg Radiol Anat* 1999;21:59-64.
43. Horrigan JM, Shellock FG, Mink JH, Deutsch AL: Magnetic resonance imaging evaluation of muscle usage associated with three exercises for rotator cuff rehabilitation. *Med Sci Sports Exerc* 1999;31:1361-1366.