

## CASE REPORT

## THE USE OF DRY NEEDLING FOR A SUBJECT WITH ACUTE ONSET OF NECK PAIN: A CASE REPORT

Ron Pavkovich, PT, DPT, Cert. DN, Cert. SMT, Dip. Osteopractic, CIDN<sup>1</sup>

**ABSTRACT**

**Background and Purpose:** Neck pain is a common complaint treated by the physical therapist. Trigger points (TrPs) have been studied as a source of neuromusculoskeletal pain, though the ability of clinicians to accurately locate a TrP is not well supported. Dry needling (DN) is an intervention utilized by physical therapists where a monofilament needle is inserted into soft tissue in order to reduce pain thereby facilitating return to prior level of function. The purpose of this case report is to report the outcomes of DN as a primary treatment intervention for acute, non-specific cervical region pain.

**Case description:** The subject was an active 64-year-old female who self-referred for cervical pain following lifting heavy boxes while moving into a new home. She had a history of multi-level cervical fusion and recurrent cervical pain that physical therapy helped to control over the past few years. Physical examination supported a diagnosis of acute cervical region strain. Objective findings included decreased cervical active range of motion (AROM) and upper extremity strength, as well as, reproduction of pain symptoms upon palpation indicating the likelihood of TrPs in the right upper trapezius, levator scapula, supraspinatus, and infra-spinatus musculature. She was treated using DN to the aforementioned muscles for two sessions, and no other interventions were performed in order to determine the effectiveness of DN as a primary intervention strategy without other interventions masking the effects of DN.

**Outcomes:** Clinically meaningful improvements were noted in pain and disability, as measured by the Neck Disability Index and Quadruple Visual Analog Scale. Physical examination denoted minimal to no change in cervical AROM (likely associated with multi-level fusion), except for right lateral flexion, and no change in shoulder flexion/abduction MMT.

**Discussion:** The patient was able to return to daily and work activities without further functional limitations caused by pain. This case report shows promising outcomes for the use of DN in the treatment of non-specific cervical region strain. Further research is recommended to determine if DN is clinically beneficial independent of other therapeutic interventions/postural corrections such as general or specific exercises targeting the affected musculature, or other “manual” therapy techniques such as manipulation or non-thrust mobilization.

**Level Of Evidence:** Level 4

**Keywords:** Cervical strain; dry needling; myofascial trigger points; neck pain

**CORRESPONDING AUTHOR**

Ron Pavkovich, PT, DPT, Cert. DN, CIDN  
Owner- Advantage Physical Therapy  
3217 Summit Square Place  
Suite 100  
Lexington, KY 40509  
(859) 263-8080- office  
(859) 263-8775- fax  
E-mail: ron@advantageptlex.com

<sup>1</sup> Advantage Physical Therapy, Lexington, KY, USA

---

## INTRODUCTION

Dry Needling (DN) has risen in the rehabilitation community to become one of the preeminent treatment strategies employed by physical therapists. There are a number of schools of thought regarding proper DN techniques in order to address a host of pathological conditions. Literature is easily found upon a search for treatment of trigger points (TrPs), but there is minimal scientific research comparing DN to other interventions. Several authors have investigated and reported the physiological make-up of a TrP, as well as the reliability of current attempts to accurately clinically diagnose a TrP.<sup>1-7</sup> TrPs have been studied extensively over the years, beginning with Simons and Travell, who originally reported that TrPs could be identified by focal tenderness to palpation along with restricted stretch range of motion when the muscle was placed on stretch.<sup>8</sup> The presence of a TrP was also described as identifiable by palpation by the presence of a local twitch response (LTR) and reproduction of predicted referred pain patterns, which matches the distribution of the subject's pain.<sup>8</sup>

A clinical diagnostic criterion for identification of a TrP consists of palpation of a tender nodule in a taught band of muscle and subject pain recognition of tender spot palpation.<sup>4</sup> Some authors, such as Hong et al.<sup>9</sup> continue to promote the notion that the (LTR) described by Simons and Travell<sup>10</sup> is necessary for maximum effectiveness of trigger point dry needling (TrP-DN), but current research by Tough et al.<sup>4</sup> indicates that of the original four criteria most commonly used to diagnose TrPs according to Simons and Travell<sup>8</sup>, LTR, and predicted pain referral pattern are no longer considered essential for diagnosis. An issue with accurate diagnosis of TrP location is the lack of a clinician's lack of ability to reliably identify a specific TrP.<sup>2,4-6</sup>

The exact mechanism(s) as to the physiological response elicited by DN is unclear. Though the literature reports the effectiveness of acupuncture, DN has not been extensively studied, and a distinction needs to be made noting that DN is not synonymous with acupuncture. The mechanisms of needle insertion, though similar in nature, are differentiated in the application and theory behind the two different types of needling interventions. Several studies

have been performed to attempt to describe the pathophysiology, biomechanical, and mechanical characteristics of TrPs, as well as, the effects of acupuncture/ DN on TrPs. A summary of these investigations provide the following proposed explanatory mechanisms:

- Afferent signal barrage from localized TrPs sensitize neuronal receptive fields in the dorsal horn, thereby widening the receptive field and activating silent synaptic connections in the same or other muscles causing pain.<sup>11,12</sup>
- Excessive acetylcholine release affects formation of the taught band causing a palpable nodule in the muscle causing localized hypoxia of the muscle caused by increased energy consumption and decreased energy supply, creating an "energy crisis" within the muscle<sup>13</sup>, and the release of energy consuming localized contracture via sarcomere lengthening leading to tissue ischemia. This situation can be positively affected by eliciting the local twitch response.<sup>14</sup>
- Analgesia may be attained via the gate control theory occurring during needle insertion (afferent pain input may be mitigated by another noxious stimulus input); the elevation of opioid peptides (endorphins, enkephalins, serotonin, and acetylcholine) in the CNS; and/ or diffuse noxious inhibitory control where the noxious stimulation regulates the pain originating area).<sup>12,15</sup>
- DN techniques may have a local and/ or remote therapeutic effect based on mechanical coupling of connective tissue and the needle thereby causing a "downstream" effect on the generation of a mechanical signal caused by needle grasp pulling (or twisting of the needle in-situ to wind collagen fibers around the needle). These downstream effects may include cell secretion, modification of extracellular matrix, enlargement and propagation of the pain signal along connective tissue planes, and afferent input modulation by changes in the connective milieu.<sup>16-19</sup>
- Multiple regions of deactivation occur in limbic, para-limbic, and subcortical gray structures (to including the nucleus accumbens, amygdala, hippocampus, para-hippocampus, hypothalamus, ventral

tegmental area, anterior cingulate, caudate nucleus, putamen, anterior insula, and the temporal pole) demonstrating modulation (decreasing pain signal intensity) of several cortical and subcortical limbic/ para-limbic structures while increasing pain-mitigating signal intensity in the somatosensory cortex.<sup>20-24</sup>

- Analgesia may occur via stimulation of the hypothalamus and mid-brain structures (endogenous anti-nociceptive modulation system) and the given the hypothalamus' descending raphe nucleus and deep periaqueductal gray (dPAG) projections, stimulation of this region may be critical for analgesia.<sup>24,25</sup>

The purpose of this case report is to illustrate the use of DN as a primary treatment intervention in a subject with acute, non-specific cervical pain. Informed consent to participate in the study was obtained by the subject prior to the start of the intervention. Human subjects research review was not required for this case report.

## CASE DESCRIPTION

The subject for this case report was an active 64-year-old female who self-referred to physical therapy for evaluation of generalized right-sided cervical regional pain following activities related to moving into a new house the day prior. She participated in lifting and carrying boxes, which led to pain in the right upper trapezius and levator scapular regions. Pain in these regions affected her ability to perform independent exercise activity, which she reported to engage in several times per week. Medical history of cervical spine fusion (C4-7) was noted. Pain was reported with all cervical active range of motion (AROM) and any activity requiring use of the right upper extremity. There were no reported symptoms of neurovascular radiculopathy such as paresthesia, anesthesia, or dysesthesia in either upper extremity. Her general health was good and absent of signs suggestive of non-musculoskeletal origin. She was already taking anti-inflammatory medication for ongoing chronic intermittent neck and low back pain. Her goal was to eliminate her increased neck pain in order to return to work as a real estate agent to finishing moving into her new house.

The outcome measures employed in this case report were the Neck Disability Index (NDI) and the Quadruple Visual Analog Scale (QVAS) [Table 1]. Upon initial

evaluation per the QVAS, the subject reported her current, average, best, and worst pain levels during the last 24-hour period. The visual analog scale (VAS) and its derivatives, such as the QVAS, have moderate to good reliability (correlation coefficient 0.60-0.77) to detect disability and high reliability for acute pain (correlation coefficient 0.76-0.84).<sup>26,27</sup> All QVAS measures are shown in Table 1. The NDI was used to assess functional disability. The NDI is a quick and moderately reliable tool that can be easily completed and has been found to have moderate to high degree reliability (0.69-0.70) and internal consistency regarding the assessment of disability.<sup>28</sup> According to Young et al.<sup>29</sup>, the minimal detectable change is 13.4 points and the minimal clinically important difference is 8.5 points. Validity is thought to be low per Young et al.,<sup>29</sup> but for a standardized, fast, and reliable measure, the NDI was chosen. The results of the NDI are shown in Table 1. Outcomes measures were assessed initially for baseline, then immediately following the initial treatment session, and at the completion of the last session.

## EXAMINATION

The subject in this case report was a long time patient of the clinic, as she has been seen over the years for various issues including neck pain. She reported pain with cervical AROM in all planes, though most significantly with bilateral rotation, right lateral flexion, and flexion and abduction of the right upper extremity.

Given the subject's previous complaints of cervical pain and history of cervical fusion, and previous shoulder pathology including rotator cuff repair, it was necessary to rule out cervical radiculopathy and pain associated with shoulder etiology. Cervical radiculopathy was ruled out via upper quarter neurological screen including dermatomal, myotomal, deep tendon reflex (DTR), and symptom centralization testing. Symptom centralization was assessed via repetitive cervical extension to rule out the likelihood of discogenic pathology. She had no complaints of upper extremity radicular symptoms, but there were reports of pain into the upper trapezius (UT) /levator scapula (LS), and posterior scapular regions (specifically the infraspinatus muscle belly and superomedial border of the scapula). Shoulder pathology was ruled out via comprehensive assessment of the shoulder

(including the tests performed for cervical radiculopathy) with added special tests focused on ruling out the following etiologies: rotator cuff injury/pathology (belly squeeze test, manual muscle testing of the cuff musculature, full can resistance test), labrum complex pathology (crank test, O'Brien's, and clunk test), biceps pathology (Speed's, Yergason's, and Dynamic Speed's), and acromioclavicular joint pathology (AC compression and manual palpation). Due to the subject's subjective reports, and based upon her previous history and current injury mechanism, differential diagnoses included cervical disc pathology, rotator cuff involvement, and pain of cervicogenic origin (specifically joint-based pathology).

Assessment of posture was performed in a seated position, rather than standing, as she reported a significant amount of pain while standing, and a standing position was not able to be tolerated per her subjective report. This included assessment of cervical positioning and shoulder complex (scapulothoracic) observation. Physical examination revealed cervical positioning at rest maintained in a mild right laterally flexed position with right shoulder depression. There was observed forward bilateral shoulder positioning while sitting in a relaxed position. No other postural abnormalities were noted.

Cervical complex and right upper extremity AROM were both assessed for deficit. An inclinometer and goniometer was used to assess AROM of the cervical spine, but was not necessary for the shoulder, as AROM was normal. According to Hole et al.,<sup>30</sup> intratester interclass correlation coefficients (ICCs) for single inclinometer assessment is as follows: 0.84 and 0.94 (flexion/ extension), 0.82 and 0.92 (lateral flexion), and 0.81 and 0.89 (rotation). For cervical AROM, the inclinometer was placed directly over

the external auditory meatus for flexion, extension, and lateral flexion. For rotation, a goniometer was utilized and used landmarks of the midline of the nose and an imaginary line drawn between the acromion processes. ROM was recorded at baseline, immediately after the first and last treatment sessions and the results are shown in Table 1. Scapulothoracic rhythm was also observed with shoulder elevation in all planes for abnormality. No deficit was observed. Right upper extremity AROM was normal, although the patient reported pain in the upper trapezius region with active elevation of the shoulder. Strength was also assessed in the right upper extremity using manual muscle testing (MMT), and the results are shown in Table 1.

An upper quarter neurological examination was performed to screen for spinal symptom etiology. This included dermatomal, myotomal, and DTR's. Dermatomal testing assessed light touch sensory palpation to the C4 to T2 dermatomal regions of the upper extremities. Myotomal testing was assessed via manual muscle testing of the same nerve root representations just mentioned. DTR's were assessed by testing the C5 through C7 nerve roots (Brachial, Radial, and Triceps) with a reflex hammer. There were no neurologic abnormalities noted.

Provocative testing was not utilized for the cervical spine, as the subjective reports of symptoms did not warrant evaluation of symptoms of radiculopathic origin. Given her cervical fusion history with hardware implantation, subjective and objective testing ruled out the need for provocative testing. Given her normal AROM and only mild strength deficit of the right shoulder, it did not appear the pain was of shoulder origin. Nonetheless, special tests including the Hawkins Kennedy (SN-sensitivity = 79%, SP-specificity = 59%),<sup>31</sup>

<b>Table 1. Outcome Measures</b>			
Outcome Measures	Initial Exam	Following Initial Treatment	Follow Second Treatment
NDI	24%	0%	0%
QVAS Current	71 cm	2 cm	2 cm
QVAS Average	71 cm	8 cm	14 cm
QVAS Best	7 cm	5 cm	1 cm
QVAS Worst	76 cm	42 cm	22 cm
NDI= Neck Disability Index QVAS= Quadruple Visual Analog Scale			

---

Neer (SN = 79%, SP = 53%),<sup>31</sup> Speed (SN = 32%, SP = 62%),<sup>31</sup> Full Can (SN = 66% pain/ 77% weakness; SP = 64% pain/ 74% weakness)<sup>32</sup>, Yergason (SN = 43%, SP = 79%),<sup>33</sup> and Crank Test (SN = 56%, SP = 46%),<sup>34</sup> tests were performed to rule out shoulder pathology, and the results of the special tests did not reveal pathology that originated glenohumeral joint complex.

Palpation revealed tender/ taught bands in the upper trapezius, levator, supraspinatus, and infraspinatus musculature on the right side. There were no autonomic responses noted (e.g. temperature change, diaphoresis, etc.) and no sensory issues were identified. Trophic changes were also absent (skin dryness, color changes, dermatomal hair loss, and edema).

### **EVALUATION/ DIAGNOSIS**

Following subjective history and physical examination, TrPs in the upper trapezius and levator scapular were suspected as the underlying pathology. According to the literature,<sup>1-7</sup> the ability to definitively ascertain the exact location of a TrP is questionable, and examiner experience plays a positive role in determining the presence of a TrP. Identification of a tender nodule in a taught band of muscle along with reproduction of the subject's subjective report of pain is the most clinically accurate way to recognize the presence of a TrP, especially in the upper trapezius muscle.<sup>2,3</sup>

Cervical AROM deficit and mild shoulder flexion and abduction strength deficits were noted. Cervical AROM was already limited due to previous multi-level cervical fusion, and pain in the upper trapezius and levator scapula regions were reported to cause decreased ability to raise her right upper extremity for daily use needs. This may or may not have contributed to strength deficit in the right shoulder. Hyperirritable taught bands were palpable in the noted musculature and flat palpation confirming the location to be used for DN was utilized. These tender bands were suggestive of TrP involvement, as described by Simons and Travell.<sup>8</sup> There was tenderness to palpation in the supraspinatus and infraspinatus muscle bellies, and the levator scapula muscle belly and insertion at the scapular superior angle.

DN was performed as outlined in the intervention section. Clinical reasoning determined DN should be the intervention employed due to the palpable

taught bands and reported pain reproduction. Given her cervical fusion history, the author chose not to employ spinal manipulation. Also, due to her reports of severe pain upon presentation, it was not believed that stretching and exercise interventions would provide the immediate pain relief the subject was seeking. This decision was also based upon the author's training through the Dry Needling Institute of the American Academy of Manipulative Therapy and Integrative Dry Needling concept, and three years of clinical experience utilizing DN for acute muscular pathology.

### **INTERVENTION**

Risks and potential complications were advised and written consent was obtained outlining common and serious adverse events associated with DN interventions. Common complications include muscle soreness, bruising, and vasovagal reaction. More serious (but rare) complications include infection, broken needle, and pneumothorax.<sup>35</sup> There were no reported contraindications to the use of DN. Contraindications include, but are not limited to: local infection, recent cancer/ history of immune suppression, bleeding disorders, current/ chronic use of anti-coagulant medications, pregnancy, compromised sterility of equipment, and lack of practitioner practical knowledge.<sup>35</sup>

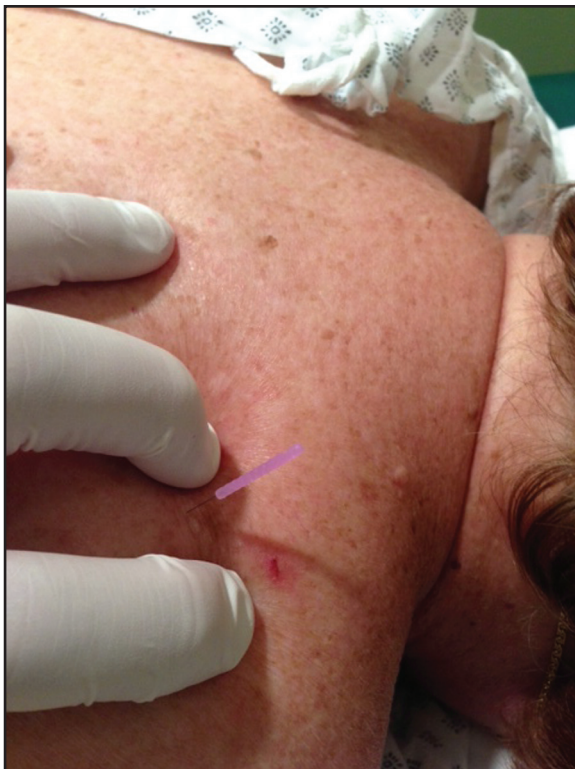The subject was treated for two sessions with 26 days between sessions. She was placed prone on a hi-low table for therapist comfort, ease of access to treatment regions, and to reduce the effects of vasovagal response, which could occur in sitting.

The following muscles were treated: the LS at the insertion on the superior angle of the scapula and in the muscle belly; the UT muscle belly at the area determined by deep palpation as a possible location of the TrP; the infraspinatus muscle belly; and the supraspinatus muscle at the tenososseus (T-O) junction superior to the scapular spine.

The needles used for the treatment of the patient in this case report were solid monofilament Seirin J-type sterile needles, No. 5 (0.25 diameter) x 30 mm. in length. Needles were used one time and discarded, as the risk of needle injury to the therapist is increased with techniques that utilize "re-sheathing" of the needles to use in other locations on the same sub-

ject.<sup>35</sup> Each needle was held in the therapist's dominant hand for application of and manipulation of the needle through the tissue. Prior to insertion of the needle(s), an application of 70% isopropyl alcohol was performed to the areas and allowed to dry for a least ten-seconds in order to reduce the resident microflora of the skin by 80-91%, yet given the fact there are an average of 1,000 microbes per square centimeter on the skin's visible surface, and 10,000 microbes per square centimeter in the ducts, glands, and follicles below the skin's surface, effective cleansing of the tissue by topical means to prevent infection is unlikely.<sup>35</sup>

All DN was performed according to the Dry Needling Institute of the American Academy of Manipulative Therapy's current educational programing.<sup>35</sup> The patient was prone for all DN insertions. DN to the LS (Figure 1) was performed using a 30 mm. needle inserted through the muscle belly and tangential to the plane of the chest wall. The DN technique utilized ten fast-in/ out movements in a cone pattern to attempt to target as many sensitive loci as possible within the tender nodule in the taught band of muscle. The needle was then wound clockwise repeatedly to attain needle grasp and was left in-situ for 15 minutes.

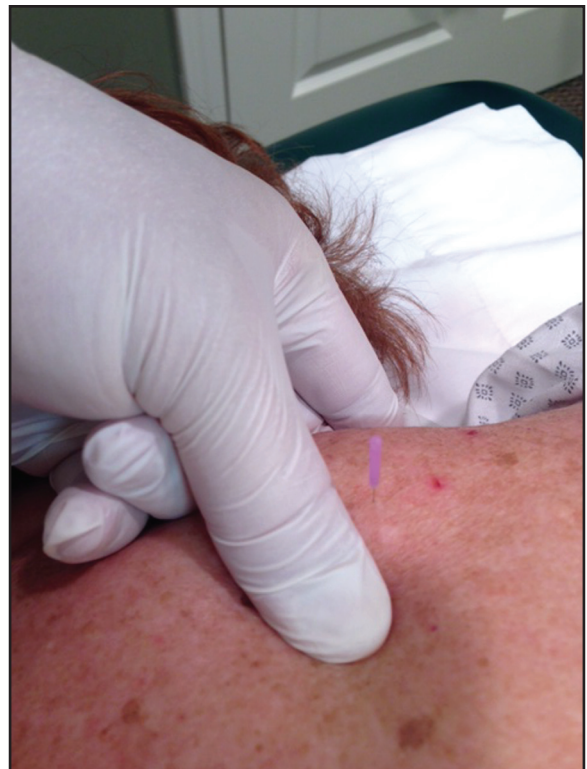

**Figure 1.** *Levator Scapula musculoskeletal junction needle insertion*

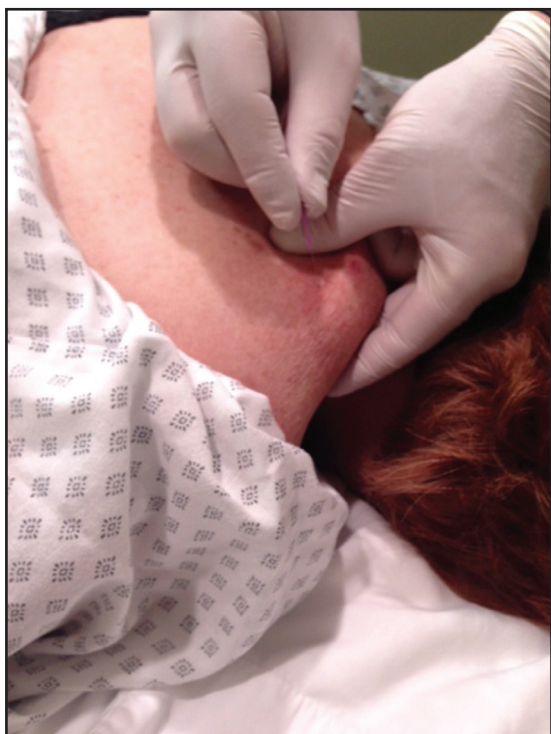
A second 30 mm needle (Figure 2) was inserted into the teno-osseus (T-O) junction of the levator at the superior angle of the scapula, and periosteal pecking was used at the T-O junction. This needle was not left in-situ unattended due to the location and proximity of the pleural cavity. The needle was removed after 20 "taps" of periosteal pecking at the T-O junction.

DN of the UT muscle (Figure 3) was performed utilizing a 30 mm needle. A tender nodule was located, using flat palpation, in the middle of the muscle belly. The needle was inserted perpendicularly through the muscle using ten fast-in/out movements in a cone pattern. As with the previous needle, this needle was wound clockwise repeatedly until needle grasp caused a slight discomfort reported by the subject. This needle was then left in-situ for 15 minutes.

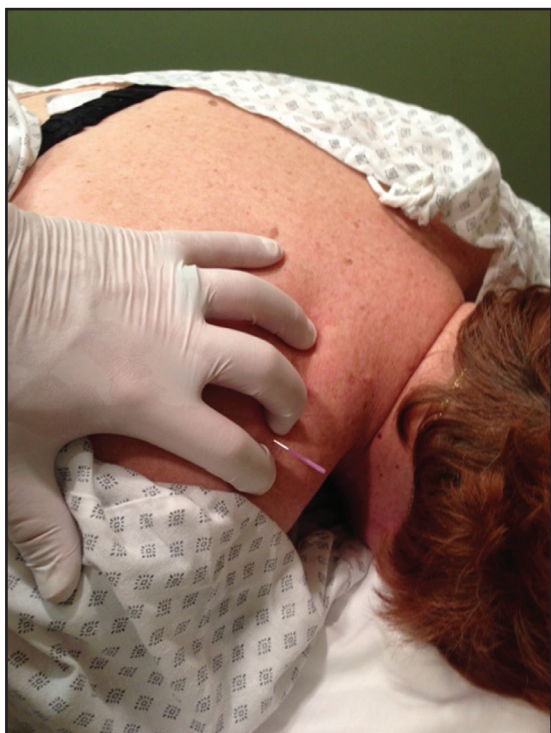DN of the supraspinatus muscle T-O junction (Figure 4) was performed using palpation to locate the tender nodule in the muscle belly. A 30 mm. needle was inserted toward the supraspinous fossa, where periosteal pecking (ten "taps") was performed just superior to the scapular spine. The needle was then left in-situ for 15 minutes.



**Figure 2.** *Levator Scapula teno-osseous junction needle insertion*

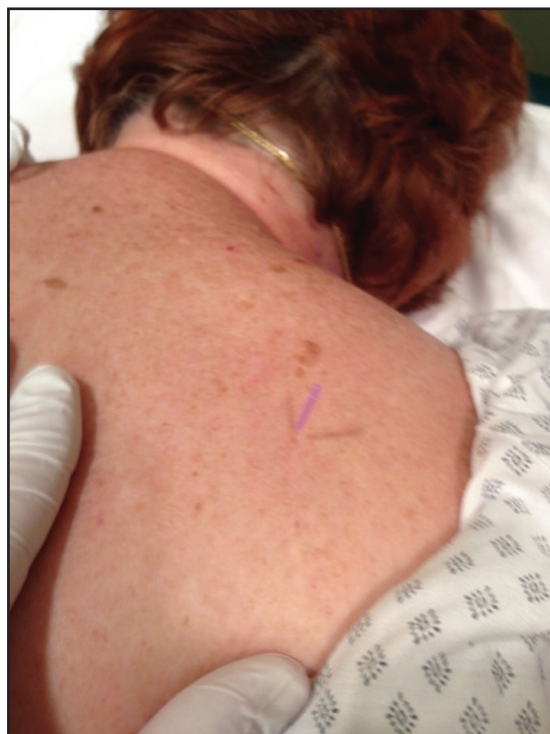

**Figure 3.** *Upper Trapezius muscle belly needle insertion*



**Figure 4.** *Supraspinatus teno-osseous junction needle insertion*

DN of the infraspinatus muscle (Figure 5) was performed using flat palpation to identify the location of the tender nodule in the taught band of muscle located one-third the distance from the scapular



**Figure 5.** *Infraspinatus muscle belly/teno-osseous junction needle insertion*

spine and center of the inferior angle of the scapula in the muscle belly. A 30 mm. needle was cautiously inserted perpendicularly to a bony backdrop, as there are rare cases of unknown scapular foraminae that need to be considered.<sup>36</sup> Periosteal pecking was performed 10 times and after twisting the needle clockwise, it was left in-situ for 15 minutes.

### **OUTCOMES**

The efficacy of the DN intervention was measured by assessment of pain and disability levels per the NDI and QVAS outcome measures, and subjective reports of improvement in the subject's overall ability and quality of life. Immediately following both treatment sessions, the subject was assessed via the NDI and QVAS outcome measures. The results of these outcome measures are shown in Table 1. The NDI improved from 24% at baseline to 0% after both DN sessions. This was maintained for almost one month following the initial treatment session (as follow up was made by phone to determine status periodically) and is considered to be a meaningful improvement based on the MDC and MDIC of the NDI. The QVAS (current) score improved from 71 cm at baseline to 2 cm at completion. The

QVAS (average) improved from 71 cm to 14 cm. The QVAS (best) improved from 7 cm to 1 cm. The QVAS (worst) improved from 76 cm to 22 cm. Though cervical AROM and shoulder MMT were recorded at baseline and following the two treatment sessions, it was not believed nor intended that these objective findings would significantly improve via DN intervention, rather, that pain and disability were the items being assessed.

Table 2 shows objective results including cervical AROM and right upper extremity strength results. The subject subjectively reported improved function with regard to daily activities such as standing, working on her computer for work needs, and with abilities such as lifting boxes for moving into her new home. Upon completion of the intervention sessions, there were no further subjective reports of functional limitation related to the recent injury, and pain was present intermittently and minimally with all daily and work activities. This was consistent with her pre-injury status, and the remaining pain was controlled with NSAID medication, which she was taking prior to the recent injury.

## DISCUSSION

The subject had no further reports of cervical region pain during daily activities, including all functional cervical mobility and right upper extremity activities. She was able to work without limitation. Significant improvement in pain and disability was seen immediately following the initial treatment intervention per the QVAS and NDI, and this carried over almost one month to the second and final treatment session. Her busy schedule did not allow for her to get back for further intervention prior to 26 days after the initial treatment session. Cervical AROM

did not change significantly, and this likely due to her previous cervical fusion. Shoulder strength did not improve following any treatment session, but this was not an expected benefit being assessed in this case report. These findings support the use of DN as an initial intervention strategy for acute, non-specific cervical strain injury.

This case report uses only a single-subject, as is typical of a case report. This is an inherent limitation to a case report, offering only results that relate to this single patient that cannot be generalized. Larger randomized control studies looking at DN interventions need to be performed in order to fully assess the effectiveness of DN as a primary intervention for acute cervical strain injuries. Longer assessment periods looking at long-term benefit versus immediate or short-term benefit also need to be assessed, as this case study showed immediate and short-term (one month) improvements in pain and disability. Further research is recommended to determine if DN is clinically beneficial independent of other therapeutic interventions such as general or specific exercises targeting the affected musculature, or other “manual” therapy techniques such as manipulation or non-thrust mobilization.

## CONCLUSIONS

DN was tolerated well by this subject, demonstrating improvements in pain and function, without adverse effects. Given her reduction in pain and improvements in reported function, the use of DN for acute cervical region strain injuries shows promise. Future research is needed to determine the full effectiveness of DN for strain-related injury of the cervical spine region, as well as, to determine longer-term outcomes.

**Table 2.** *Objective Measurements for Active Range of Motion and Manual Muscle Tests*

Objective Measures	Cervical AROM (flexion)	Cervical AROM (extension)	Cervical AROM (right side-bending)	Cervical AROM (left side-bending)	Cervical AROM (right rotation)	Cervical AROM (left rotation)	Right Shoulder Strength (flexion)	Right Shoulder Strength (abduction)
Initial/Baseline	60°	40°	35°	35°	60°	60°	4/5	4/5
Treatment #1	65°	45°	42°	37°	60°	60°	4/5	4/5
Treatment #2	65°	40°	45°	35°	60°	60°	4/5	4/5



---

## REFERENCES

1. Hong CZ. Pathophysiology of myofascial trigger point. *J Formos Med Assoc.* 1996;95(2):93-104.
2. Gerwin RD, Shannon S, Hong C-Z, Hubbard D, Gevirtz R. Interrater reliability in myofascial trigger point examination. *Pain.* 1997;69(1-2):65-73.
3. Sciotti VM, Mittak VL, DiMarco L, et al. Clinical precision of myofascial trigger point location in the trapezius muscle. *Pain.* 2001;93(3):259-266.
4. Tough EA, White AR, Richards S, Campbell J. Variability of Criteria Used to Diagnose Myofascial Trigger Point Pain Syndrome—Evidence From a Review of the Literature. *Clin J Pain.* 2007;23(3):278-286.
5. Myburgh C, Larsen AH, Hartvigsen J. A Systematic, Critical Review of Manual Palpation for Identifying Myofascial Trigger Points: Evidence and Clinical Significance. *Arch Phys Med Rehabil.* 2008;89(6):1169-1176.
6. Lucas N, Macaskill P, Irwig L, Moran R, Bogduk N. Reliability of Physical Examination for Diagnosis of Myofascial Trigger Points: A Systematic Review of the Literature. *Clin J Pain.* 2009;25(1):80-89.
7. Myburgh C, Lauridsen HH, Larsen AH, Hartvigsen J. Standardized manual palpation of myofascial trigger points in relation to neck/shoulder pain; the influence of clinical experience on inter-examiner reproducibility. *Man Ther.* 2011;16(2):136-140.
8. Simons DG, Travell J. Myofascial trigger points, a possible explanation. *Pain.* 1981;10(1):106-109.
9. Hong C-Z. Lidocaine injection versus dry needling to Myofascial Trigger Point: The Importance of the Local Twitch Response. *Am J Phys Med Rehabil.* 1994;73(4):256-263.
10. Simons DG, Travell JG. Myofascial origins of low back pain. 1. Principles of diagnosis and treatment. *Postgrad Med.* 1983;73(2):66, 68-70, 73 passim.
11. Hong C-Z, Kuan T-S, Chen J-T, Chen S-M. Referred pain elicited by palpation and by needling of myofascial trigger points: A comparison. *Arch Phys Med Rehabil.* 78(9):957-960.
12. Hsieh YL, Kao MJ, Kuan TS, Chen SM, Chen JT, Hong CZ. Dry needling to a key myofascial trigger point may reduce the irritability of satellite MTrPs. *Am J Phys Med Rehabil.* 2007;86(5):397-403.
13. Hong C-Z. Myofascial trigger points: pathophysiology and correlation with acupuncture points. *Acupuncture in Medicine.* 2000;18(1):41-47.
14. Chu J. Does EMG (dry needling) reduce myofascial pain symptoms due to cervical nerve root irritation? *Electromyogr Clin Neurophysiol.* 1997;37(5):259-272.
15. Hsieh Y-L, Chou L-W, Joe Y-S, Hong C-Z. Spinal Cord Mechanism Involving the Remote Effects of Dry Needling on the Irritability of Myofascial Trigger Spots in Rabbit Skeletal Muscle. *Arch Phys Med Rehabil.* 2011;92(7):1098-1105.
16. Langevin HM, Churchill DL, Cipolla MJ. Mechanical signaling through connective tissue: a mechanism for the therapeutic effect of acupuncture. *The FASEB Journal.* 2001;15(12):2275-2282.
17. Langevin HM, Churchill DL, Fox JR, Badger GJ, Garra BS, Krag MH. *Biomechanical response to acupuncture needling in humans.* Vol 912001.
18. Langevin HM, Bouffard NA, Badger GJ, Iatridis JC, Howe AK. *Dynamic fibroblast cytoskeletal response to subcutaneous tissue stretch ex vivo and in vivo.* Vol 2882005.
19. Langevin HM, Bouffard NA, Badger GJ, Churchill DL, Howe AK. Subcutaneous tissue fibroblast cytoskeletal remodeling induced by acupuncture: Evidence for a mechanotransduction-based mechanism. *J Cell Phys.* 2006;207(3):767-774.
20. Hui KKS, Liu J, Makris N, et al. Acupuncture modulates the limbic system and subcortical gray structures of the human brain: Evidence from fMRI studies in normal subjects. *Human Brain Mapping.* 2000;9(1):13-25.
21. Biella G, Sotgiu ML, Pellegata G, Paulesu E, Castiglioni I, Fazio F. Acupuncture Produces Central Activations in Pain Regions. *NeuroImage.* 2001;14(1):60-66.
22. Hui KKS, Liu J, Marina O, et al. The integrated response of the human cerebro-cerebellar and limbic systems to acupuncture stimulation at ST 36 as evidenced by fMRI. *NeuroImage.* 2005;27(3):479-496.
23. Napadow V, Makris N, Liu J, Kettner NW, Kwong KK, Hui KKS. Effects of electroacupuncture versus manual acupuncture on the human brain as measured by fMRI. *Human Brain Mapping.* 2005;24(3):193-205.
24. Napadow V, Kettner N, Liu J, et al. Hypothalamus and amygdala response to acupuncture stimuli in carpal tunnel syndrome. *Pain.* 2007;130(3):254-266.
25. Hsieh J-C, Tu C-H, Chen F-P, et al. Activation of the hypothalamus characterizes the acupuncture stimulation at the analgesic point in human: a positron emission tomography study. *Neuroscience Letters.* 2001;307(2):105-108.
26. Boonstra AM, Schiphorst Preuper HR, Reneman MF, Posthumus JB, Stewart RE. Reliability and validity of the visual analogue scale for disability in patients with chronic musculoskeletal pain. *International journal of rehabilitation research. Internationale Zeitschrift fur Rehabilitationsforschung. Revue internationale de recherches de readaptation.* 2008;31(2):165-169.

- 
27. Bijur PE, Silver W, Gallagher EJ. Reliability of the visual analog scale for measurement of acute pain. *Acad Emerg Med.* 2001;8(12):1153-1157.
  28. Vernon H, Mior S. The Neck Disability Index: a study of reliability and validity. *J Manipulative Physiol Ther.* 1991;14(7):409-415.
  29. Young IA, Cleland JA, Michener LA, Brown C. Reliability, construct validity, and responsiveness of the neck disability index, patient-specific functional scale, and numeric pain rating scale in patients with cervical radiculopathy. *Am J Phys Med Rehabil.* 2010;89(10):831-839.
  30. Hole DE, Cook JM, Bolton JE. Reliability and concurrent validity of two instruments for measuring cervical range of motion: effects of age and gender. *Man Ther.* 1995;1(1):36-42.
  31. Hegedus EJ, Goode A, Campbell S, et al. Physical examination tests of the shoulder: a systematic review with meta-analysis of individual tests. *Br J Sports Med.* 2008;42(2):80-92.
  32. Beaudreuil J, Nizard R, Thomas T, et al. Contribution of clinical tests to the diagnosis of rotator cuff disease: A systematic literature review. *Joint Bone Spine.* 2009;76(1):15-19.
  33. Holtby R, Razmjou H. Accuracy of the Speed's and Yergason's tests in detecting biceps pathology and SLAP lesions: comparison with arthroscopic findings. *J of Arthro Rel Surg.* 2004;20(3):231-236.
  34. Stetson WB, Templin K. The Crank Test, the O'Brien Test, and Routine Magnetic Resonance Imaging Scans in the Diagnosis of Labral Tears. *Am J Sports Med.* 2002;30(6):806-809.
  35. Dunning J. DN-1: Dry Needling for Craniofacial, Cervicothoracic & Upper Extremity COnditions: an Evidence-Based Approach. Montgomery, AL: Dry Needling Institute of the American Academy of Manipulative Therapy; 2012:256.
  36. Pate D, Kursunoglu S, Resnick D, Resnik C. Scapular foramina. *Skeletal Radiol.* 1985;14(4):270-275.