



Dry needling as a novel intervention for cervicogenic somatosensory tinnitus: a case study

Aaron Womack PT, FAAOMPT^{a,b}, Raymond Butts DPT, PhD, MSc^{b,c}, and James Dunning DPT, PhD, MSc, FAAOMPT^{b,d}

^aAlliance Health Midwest Rehabilitation, Midwest City, OK, USA; ^bAmerican Academy of Manipulative Therapy, Montgomery, AL, USA; ^cResearch Physical Therapy Specialists, Columbia, SC, USA; ^dMontgomery Osteopractic Physiotherapy and Acupuncture Clinic, Montgomery, AL, USA

ABSTRACT

Tinnitus is defined as conscious perception of sound in the absence of a corresponding external stimulus. A condition that affects 10 – 15% of the adult population, tinnitus may be caused by an interaction between the somatosensory and auditory system, more formally known as somatosensory tinnitus. Cervicogenic somatosensory tinnitus is a subgroup of somatosensory tinnitus involving anatomical structures and physiological mechanisms associated with the cervical spine. A limited number of studies have reported inconsistent outcomes for treating cervicogenic somatosensory tinnitus with conservative treatment strategies such as manual therapy and exercise. However, dry needling is a skilled, manual therapy intervention that has recently gained popularity among the physical therapy profession that may be useful for both evaluating and treating the condition. The following case report describes the use of dry needling to evaluate and treat a patient with cervical somatosensory tinnitus and concurrent cervicogenic headaches. Physical therapy that targeted the muscles of the upper cervical spine with dry needling resulted in a meaningful reduction in cervicogenic somatosensory tinnitus, and the improvements persisted at 1-year follow-up. Further research, including randomized control trials, is warranted to fully determine the potential of dry needling to treat cervicogenic somatosensory tinnitus.

ARTICLE HISTORY

Received 1 September 2019
Revised 1 July 2020
Accepted 17 August 2020

KEYWORDS

Cervicogenic tinnitus;
somatosensory tinnitus;
cervicogenic headache; dry
needling

Introduction

Tinnitus is “the conscious perception of an auditory sensation in the absence of a corresponding external stimulus” (Baguley, McFerran, and Hall, 2013). A condition that affects between 10 and 15% of the adult population, tinnitus can be classified as either subjective or objective (Baguley, McFerran, and Hall, 2013). In subjective tinnitus, only the affected individual can hear the auditory sensations (Baguley, McFerran, and Hall, 2013). In contrast, both the affected individual and outside observers can hear auditory sensations secondary to objective tinnitus (Baguley, McFerran, and Hall, 2013). For the purpose of this study, only subjective tinnitus will be considered.

Subjective tinnitus may be due to multiple pathophysiological causes, including otological, orofacial, neurological, cardiovascular, pharmacological, and psychological issues, which may alter the spontaneous firing rate and neural synchrony of central auditory neurons, potentially causing neuroplastic adaptation (Baguley, McFerran, and Hall, 2013; Levine and Oron, 2015). Somatosensory tinnitus (ST) is a subgroup of subjective tinnitus that may be due to the interaction

of the somatosensory and auditory system (Levine, 1999). Both primary and secondary somatic sensory neurons of the head, neck, face, arms, and trunk interact with the auditory system by providing afferent information to the cochlear nucleus (Shore, Zhou, and Koehler, 2007). More specifically, the cochlear nucleus receives primary projections from the C2 dorsal root ganglion (DRG) and the ophthalmic and mandibular centers of the trigeminal ganglion (TG) (Shore, Zhou, and Koehler, 2007; Zhan, Pongstaporn, and Ryugo, 2006). The cochlear nerve and the inferior colliculus also receive secondary projections from the spinal aspect of the trigeminal nucleus and from the nuclei of the dorsal column medial lemniscus pathway (Shore, Zhou, and Koehler, 2007; Zhou and Shore, 2004). Therefore, the added stimulation of the cochlear nucleus and/or inferior colliculus by the trigeminal nucleus, the dorsal root ganglia and/or the dorsal column could potentially alter the firing rates, leading to spontaneous neural activity from “non-sound driven” sources, thereby increasing the perceived loudness (or intensity) of sounds (Levine, 1999; Shore, Zhou, and Koehler, 2007). Furthermore, neural synchrony could account for changes in pitch associated with ST (Shore, Zhou, and Koehler, 2007).

According to Sanchez and Rocha (2011), ST is clinically relevant when a patient presents with at least one of the following occurrences prior to the onset of tinnitus: 1) history of head or neck trauma; 2) tinnitus associated with some manipulation of the teeth, jaw or cervical spine, including digital pressure of myofascial trigger points and/or active movement of the neck, shoulder or mandible; 3) recurrent pain episodes in head, neck or shoulder girdle; 4) temporal coincidence of appearance or increase of both pain and tinnitus; 5) increase of tinnitus during inadequate postures during rest, walking, working or sleeping; and 6) intense bruxism periods during the day or night.

Cervicogenic somatosensory tinnitus (CST) is a subgroup of ST involving anatomical structures and physiological mechanisms of the cervical region (Oostendorp et al., 2016a). Oostendorp et al. (2016a) further reported clinical criteria specifically related to the diagnosis of CST, which include: 1) neck pain; 2) impairment of cervical active range of motion (AROM), preferably rotation; 3) modulation of tinnitus by head and neck movements and/or posture; and 4) tenderness of cervical-occipital muscles. Notably, some of these criteria overlap with the diagnostic criteria for cervicogenic headache (CH) and/or cervicogenic dizziness (Oostendorp et al., 2016a).

Physical therapy has been considered as an intervention for CST in only a limited number of studies (Latifpour, Grenner, and Sjordahl, 2009; Michiels et al., 2016; Oostendorp et al., 2016a; Sanchez and Rocha, 2011). Latifpour, Grenner, and Sjordahl (2009) reported a greater improvement in tinnitus loudness after application of stretching, posture exercises, and acupuncture compared to controls. Sanchez and Rocha (2011) also reviewed five case reports in which cervical spine mobilizations and stretching of suboccipital muscles decreased the intensity of the tinnitus in five patients. Michiels et al. (2016) reported that multimodal physical therapy targeting the cervical spine improved symptoms of subjective tinnitus. Oostendorp et al. (2016a) further recommended a combined approach consisting of physical therapy and patient-based tinnitus education for subjective tinnitus and tinnitus-related sensitization.

A number of studies have also used acupuncture to reduce symptoms related to tinnitus (Doi et al., 2016; Low et al., 2017; Marks, Emery, and Onisiphorou, 1984; Okada et al., 2006). Doi et al. (2016) reported significant reductions in sound intensity and improvements in function in patients with tinnitus following 10 sessions (40-minute treatments twice per week over 5 weeks) of electroacupuncture compared to patients receiving no treatment. While Low et al. (2017) did not find that electroacupuncture was beneficial in treating patients

with somatic vs. non-somatic tinnitus, patients in the somatic tinnitus group that reported symptom modulation with forceful muscle contraction maneuvers demonstrated a favorable response to the treatment. Notably, these studies (Doi et al., 2016; Low et al., 2017; Marks, Emery, and Onisiphorou, 1984; Okada et al., 2006) focused on traditional acupuncture points associated with tinnitus primarily in the periauricular region.

Dry needling (DN) is a procedure using thin filiform needles to penetrate the skin that has gained popularity among Western-based health care practitioners (i.e. physicians, osteopaths, chiropractors, and physical therapists) over the last 10 years for the treatment of neuromusculoskeletal conditions (Dunning et al., 2014). However, while the terminology, philosophy, and theoretical constructs differ between Western-based DN and traditional Chinese acupuncture, the procedure of inserting monofilaments into the body is essentially the same (Dunning et al., 2014). To date, no specific studies related to the effect of DN on CST have been published. From the authors' knowledge this is the first case report that describes the use of DN to evaluate and treat this patient population.

Case description

History

A 41-year old female was referred to physical therapy by her neurologist with a diagnosis of occipital neuralgia. She presented to the clinic with complaints of headaches, cervical pain and tinnitus. The headache pain was located in the occipital region. While the symptoms in the cervical spine spanned from C1-C7, the patient reported the worst pain in the suboccipital region, which she rated as 10/10 per numeric pain rating scale (NPRS) (Farrar et al., 2001). Moreover, the head and neck pain were accompanied by 10/10 tinnitus, bilaterally, per numeric rating scale (NRS) (Landgrebe et al., 2012).

The patient reported having recurrent headaches for more than 20 years, which seemed to worsen following multiple motor vehicle accidents (MVA). She was diagnosed with occipital neuralgia nine years earlier by a neurologist. Around the same time, she noted an insidious onset of symptoms consistent with CST that would intermittently accompany her headaches. The headaches and tinnitus presented bilaterally, but the intensity of the symptoms was greater on the right side. At the time of onset, she underwent a hearing evaluation that revealed a 10% bilateral loss of hearing. While the ringing in the ears slowly decreased over a six-month time period, the patient continued with

intermittent bouts of tinnitus after loud concerts, increased stress, concurrent headaches, and prolonged sitting postures (e.g. driving).

The patient underwent cervical nerve blocks and radiofrequency nerve ablations for her headaches but could not recall the specific spinal levels that were targeted. While the ablations seemed to provide relief, the decreased headache intensity lasted for only six months following each treatment. At the time of the clinical assessment reported in this article, the patient had not undergone nerve blocks or ablations during the past year. The patient also reported temporary relief from her headache and tinnitus after hot baths, ice packs, and rest. Nevertheless, the patient noted a significant worsening in her headache and tinnitus symptoms over the last 6 months. Additionally, the CST limited her ability to participate in conversations and attend her daughter's swimming practices due to the unique acoustics of the room. At the time of the clinical assessment, her tinnitus varied from 7/10 to 10/10 per NRS, bilaterally. While the NRS is been widely used to rate tinnitus symptoms, it has not been systematically validated for use in this patient population (Landgrebe et al., 2012). The patient scored a 60/100 on the Tinnitus Handicap Inventory (THI), a valid (Newman, Jacobson, and Spitzer, 1996) and reliable (Newman, Jacobson, and Spitzer, 1996; Newman, Sandridge, and Jacobson, 1998) outcome measure for tinnitus that has been used in multiple trials (Langguth et al., 2007). She also scored a 36/50 on the Neck Disability Index (NDI), which is the most common outcome measure for cervical pain (MacDermid et al., 2009) and has been shown to be a valid and reliable measure for CH (Young et al., 2019).

The patient was a nonsmoker and denied any history of cardiovascular disease, diabetes, hypertension, high cholesterol, osteoporosis, rheumatoid arthritis, cancer or significant surgeries. However, she was taking Wellbutrin for depression. At the time of her physical therapy treatment, she was not employed.

Clinical findings

The physical examination (PE) was conducted by a physical therapist with 20 years of experience, certified in spinal manipulation and dry needling. Additionally, the therapist was a fellow-in-training in an accredited manual physical therapy fellowship program. The patient demonstrated full cervical AROM, and cervical myotome, dermatome, and cranial nerve screening were negative. While palpation of the cervical paraspinals, upper trapezius, splenius capitis, semispinalis capitis, obliquus capitis superior, obliquus capitis inferior, rectus capitis posterior major and rectus capitis posterior

minor muscles seemed to provoke the patient's headache and tinnitus, the sternocleidomastoid, masseter, temporalis, and frontalis muscles did not. Additionally, she did not present with temporomandibular joint pain or increased tinnitus with active jaw movement. The patient reported occasional, diffuse pain in the posterior occipital region, but she was not tender to palpation in that region during the PE. Although the patient presented with lower cervical and upper thoracic pain, palpation and passive joint mobility testing of the lower cervical and upper thoracic region had no effect on her headache or tinnitus symptoms.

Diagnostic Assessment

Importantly, the patient presented with five out of six symptoms of ST (Sanchez and Rocha, 2011), including: 1) history of head or neck trauma secondary to multiple MVAs; 2) tinnitus associated with some manipulation of the teeth, jaw or cervical spine, including digital pressure of myofascial trigger points and/or active movement of the neck, shoulder or mandible; 3) recurrent pain episodes in head, neck or shoulder girdle; 4) temporal coincidence of appearance or increase of both pain and tinnitus; and 5) increase of tinnitus during inadequate postures during rest, walking, working or sleeping. The only symptom not present was intense bruxism periods during the day or night. Additionally, she presented with three out of four symptoms indicative of CST (Oostendorp et al., 2016b), including: 1) neck pain; 2) modulation of tinnitus by head and neck movements and/or posture; and 3) tenderness of cervical-occipital muscles. She did not present with limited cervical AROM.

Therapeutic interventions

At the initial evaluation, the patient was unable to tolerate cervical mobilization. However, she did benefit from a high velocity low amplitude (HVLA) thrust manipulation targeting the upper thoracic spine, as it alleviated some general lower cervical pain. While thoracic manipulations were provided during all subsequent visits to alleviate thoracic and lower cervical pain, manual techniques targeting the thoracic spine did not evoke an immediate change of the patient's headache or tinnitus symptoms. During the 2nd treatment, which was two days after the initial evaluation, the patient was able tolerate DN of the upper trapezius, splenius capitis, semispinalis capitis, obliquus capitis superior, obliquus capitis inferior, rectus capitis posterior major and rectus capitis posterior minor muscles, bilaterally. Seiren needles (0.25 mm gauge) were inserted and left in situ for

20 minutes. Needles were inserted for 20 minutes and manually stimulated every 3–4 minutes via unidirectional winding to elicit familiar tinnitus symptoms. While needle insertion and stimulation initially provoked the patient's headache and tinnitus symptoms, she reported an immediate decrease in symptoms related to tinnitus from 7/10 to 3/10 on the right side and 7/10 to 0/10 on the left side upon removal. Additionally, she noted an improvement in her headache pain from a 4/10 to a 0/10.

Dry needling was applied during all treatment sessions with minimal variation of location with one exception. During the 4th treatment, which took place eight days after the initial clinical assessment, the patient reported no headache or tinnitus symptoms. However, she experienced a headache 24-hours earlier and requested treatment to address the occipital region. In addition to an upper cervical HVLA thrust manipulation, targeting the C1-C2 facet joints, she received dry needling to the sensitive portion of the occipitalis muscle. Needles were left in situ for 20 minutes with manual stimulation (i.e. unidirectional winding) every 3–4 minutes. Although the patient reported reduced tinnitus symptoms, she did not note an improvement in intermittent headache symptoms following the treatment.

As a result, treatments 7–9 included dry needling of the same cervical musculature as previously described with the addition of electrical stimulation, consistent with the literature on tension type, migraine and cervicogenic headaches (Hao, Xue, Dong, and Zheng, 2013; Ishiyama et al., 2018; Zhang, Liu, and Jiang, 2014). Needles were stimulated at 3–10 Hz frequency and 250 microseconds phase duration via a sweep setting. The addition of electrical stimulation resulted in a significant reduction in headaches and symptoms related to tinnitus.

Given the patient's concerns about health-care insurance end-of-year deductibles, she elected to undergo spinal nerve root blocks (SNRB) for spinal nerves C2-C7, bilaterally, 24 hours after the 9th physical therapy treatment. While her tinnitus and headache symptoms significantly increased following the SNRB procedure, all symptoms returned to pre-SNRB levels 8-days later. The patient received one additional treatment of DN with electrical stimulation. Afterward, the patient reported a complete resolution of her headaches and tinnitus, bilaterally, which continued over the next 3 weeks. As a result, she was discharged from PT.

It is worth noting that cervical manipulation and cervical exercises (Jull et al., 2002) were also performed on treatment six (33-days post evaluation) and seven (43-days post evaluation), respectively, secondary to

the patient's report of headaches. However, neither treatment improved the patient's headaches, and they were, therefore, discontinued. A complete list of physical therapy interventions and the patient's symptoms before and after each treatment is listed in Table 1.

Follow-up and outcomes

A 10-point NRS for tinnitus was used to qualify tinnitus symptoms and headache pain, and the THI were used to measure changes in function. While the NRS for has not been validated for tinnitus in this patient population, it is widely used throughout the literature (Landgrebe et al., 2012). The patient subjectively reported consistent within-treatment improvements via the NRS. While she reported 10/10 tinnitus symptoms per NRS, bilaterally, during evaluation, she noted 0/10 symptoms, bilaterally, at discharge (Figures 3 and 4). The scores for the THI were as follows: baseline: 60/100; six weeks: 26/100; nine weeks: 24/100; and thirteen weeks: 4/100. While there is not currently an established minimal clinically important difference (MCID) on the THI for somatosensory tinnitus, the patient subjectively reported a meaningful change at all time-points post-evaluation (Figure 1).

While the focus of this article was CST, the intervention was altered because the patient's headaches and NDI score did not change at Week-6 compared to baseline. As such, the patient's NDI scores were also included as part of this case report (Figure 2). Notably, the patient's headaches and NDI score improved at Week-9 (24/50) and Week -13 (18/50) only after electric dry needling. The MCID for the NDI in relation to headaches has been suggested to be 5.5 to 7.5 points (Young et al., 2019).

At 12-months, the patient subjectively reported a significant reduction in symptoms related to CST and CH. The THI and NDI scores were 30/100 and 17/50, respectively (Figures 1 and 2, respectively). She also noted 0/10 sub-occipital/head pain per NPRS and intermittent tinnitus symptoms (0–4/10 per NRS), bilaterally. Specifically, she experienced short bouts of tinnitus following concerts, but the symptoms quickly resolved after the event. While the patient did undergo a single unspecified cervical nerve ablation approximately 1-month after discharge from physical therapy as a prophylactic treatment for headaches, the ablation did not affect her tinnitus symptoms.

Discussion

The purpose of this report was to determine the effects of a physical therapy intervention, which included DN, on a patient that presented with symptoms consistent with CST. The patient reported a significant change in THI scores from the initial visit to week six with no

Table 1. Summary of Interventions and Outcomes.

| Number | Days | Thoracic Spinal Manipulation | Cervical Spinal Manipulation | Dry Needling | Cervical Exercises | Tinnitus (NRS) pre | Tinnitus (NRS) post | Headaches (NRS) pre | Headaches (NRS) post |
|--------------------------|------|------------------------------|------------------------------|---|--------------------|-------------------------|-------------------------|---------------------|----------------------|
| Evaluation/ Treatment 1 | 0 | X | | No treatment provided | | 10/10 Right, 10/10 Left | 10/10 Right, 10/10 Left | 10/10 | 10/10 |
| Treatment 2 | 2 | X | | CST DN Protocol: upper trapezius, splenius capitis, semispinalis capitis, obliquus capitis superior and inferior, rectus capitis posterior major and rectus capitis posterior minor (bilaterally) | | 7/10 Right, 7/10 Left | 3/10 Right, 0/10 Left | 4/10 | 0/10 |
| Treatment 3 | 5 | X | | CST DN Protocol (Bilaterally) | | 2/10 Right, 0/10 Left | 0/10 Bilaterally | 0/10 | 0/10 |
| Treatment 4 | 8 | X | X | Occipitalis with manual stimulation (bilaterally) | | 0/10 Bilaterally | 0/10 Bilaterally | 0/10 | 0/10 |
| Treatment 5 | 21 | X | | CST DN Protocol (Right Side Only) | | 8/10 Right, 0/10 Left | 8/10 Right, 0/10 Left | 5/10 | 5/10 |
| Treatment 6 | 33 | X | X | CST DN Protocol (Bilaterally) | | 0/10 Right, 0/10 Left | 0/10 Right, 0/10 Left | 8/10 | 8/10 |
| Treatment 7 | 43 | X | | CST DN Protocol (Bilaterally) with Electrical Stimulation | X | 6/10 Right, 0/10 Left | 1–2/10 Right, 0/10 left | 6/10 | 0/10 |
| Treatment 8 | 47 | X | | CST DN Protocol (Bilaterally) with Electrical Stimulation | | 0/10 Bilaterally | 1–2/10 Right, 0/10 left | 5/10 | 0/10 |
| Treatment 9 | 54 | X | | CST DN Protocol (Bilaterally) with Electrical Stimulation | | 0/10 Bilaterally | 0/10 Bilaterally | 0/10 | 0/10 |
| Spinal Nerve Root Blocks | 55 | | | | | | | | |
| Treatment 10 | 63 | X | | CST DN Protocol (Bilaterally) with Electrical Stimulation | | 0/10 Bilaterally | 0/10 Bilaterally | 5/10 | 0/10 |
| Treatment 11 | 70 | X | | No treatment | | 0/10 Bilaterally | 0/10 Bilaterally | 2/10 | 0/10 |
| Treatment 12 | 82 | X | | No treatment | | 0/10 Bilaterally | 0/10 Bilaterally | 0/10 | 0/10 |

significant change from week six to week nine. However, the patient further reported consistent reductions in her tinnitus symptoms per NRS. At week nine, electrical stimulation with DN was added to address her headache symptoms, and the patient continued to report improvements in her tinnitus and headache symptoms, thereafter. Importantly, the patient continued to note meaningful improvements in her tinnitus per THI and NRS as well as headaches per NDI at the 12-month follow-up (Figure 1–4).

Given that the underlying proposed criteria for determining both CST and CH are similar (Oostendorp et al., 2016b), it is worth noting the timeline of the patient’s recovery. While the patient reported a significant reduction in symptoms related to CST after the second treatment, her headaches did not significantly improve per her NDI score until electrical stimulation was added to the dry needling protocol. The manual stimulation of the needles appeared to be more effective for symptoms related to CST, while the addition of electrical

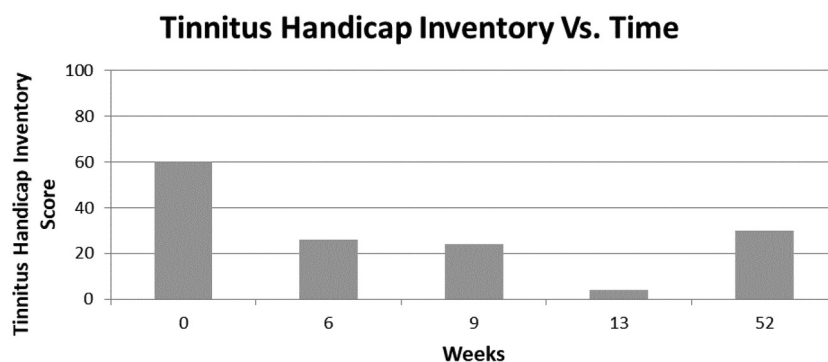


Figure 1. Tinnitus handicap inventory.

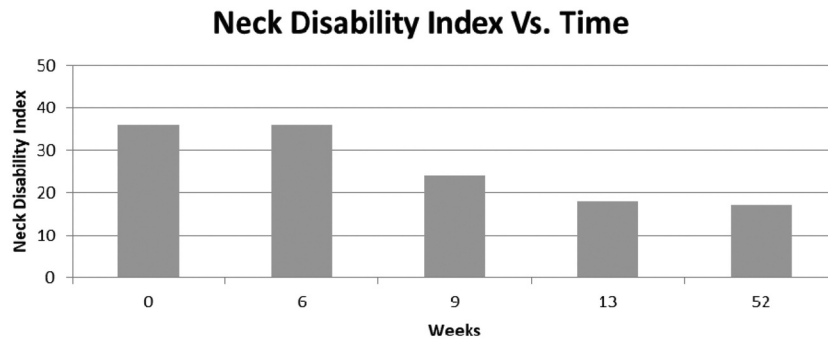


Figure 2. Neck disability index.

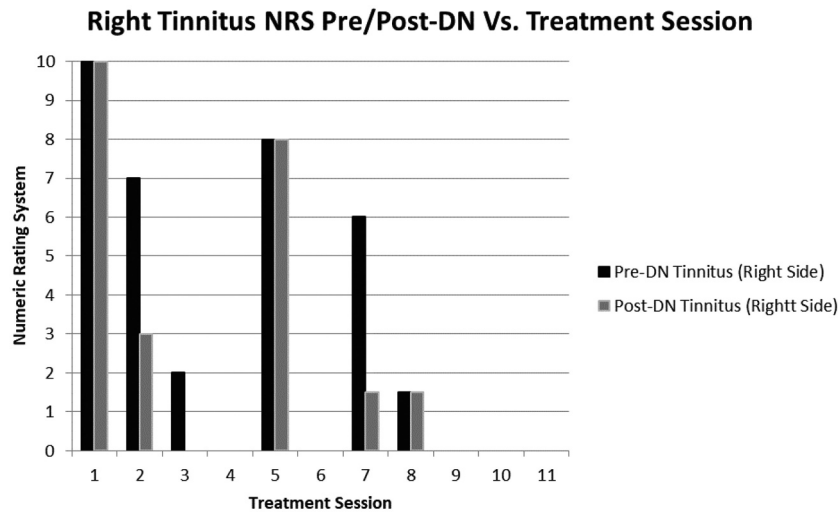


Figure 3. Numeric rating scale for Pre/Post-DN Right-sided Tinnitus.

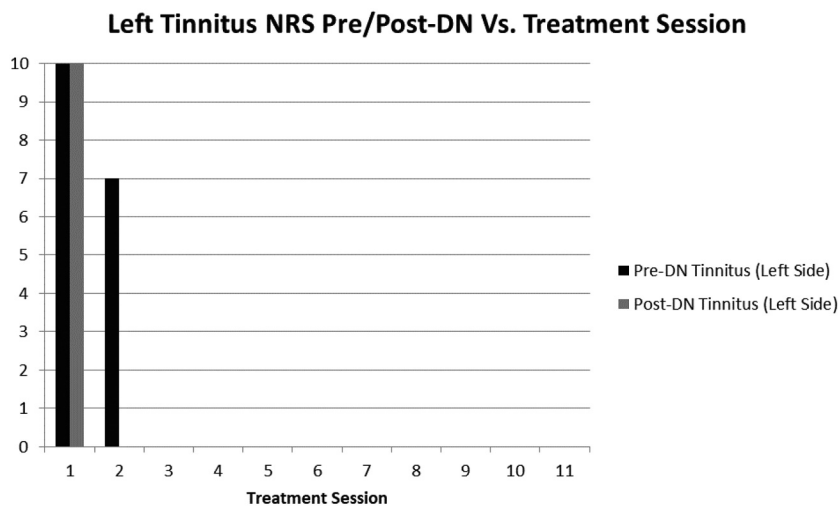


Figure 4. Numeric rating scale for Pre/Post-DN Left-sided Tinnitus.

stimulation appeared to more directly address her headaches. This may further highlight the differences in underlying mechanisms of CST and CH. While there

may be a physiologic or temporal relationship between the presentation CST and CH, a similar, but not identical underlying cervicogenic mechanism may result in

the co-morbid presentation of both conditions. This may have clinical implications, as the treatment strategies required for each condition may be unique.

The effect of DN on CST may be directly related to the effect of mechanotransduction via the dense concentration of muscle spindles located in the suboccipital muscles (Boyd-Clark, Briggs, and Galea, 2002; Kulkarni, Chandy, and Babu, 2001; Liu, Thornell, and Pedrosa-Domellöf, 2003), resulting in an alteration of afferent somatosensory signaling. This could affect the spontaneous neural activity to the cochlear nucleus and/or inferior colliculus from the trigeminocervical nucleus, the dorsal root ganglia and/or the dorsal column that has been theorized to be the basis for somatosensory tinnitus (Levine, 1999; Shore, Zhou, and Koehler, 2007). Kanold and Young (2001) reported that direct receptor stimulation via structures such as muscle spindles innervated by cervical spinal nerve branches resulted in an inhibition of somatosensory activity to the dorsal cochlear nucleus.

In contrast, Kanold and Young (2001) further reported that cutaneous somatosensory stimulation via cervical spinal branches had no effect on somatosensory activity to the dorsal cochlear nucleus. This observation is consistent with the findings of the present case as the patient's CST improved after deeper, manual needle stimulation but did not significantly change with the addition of more superficial electrical stimulation.

Additionally, Shore, Zhou, and Koehler (2007) reported that nociceptive projections to the cochlear nucleus (CN) appear to be lacking. The secondary neurons in the anterolateral system that mediate pain and temperature have not been reported to project to the auditory structures (Shore, Zhou, and Koehler, 2007). Furthermore, the CN contains very few nociceptive afferents from the spinal trigeminal nucleus (Shore, Zhou, and Koehler, 2007). Thus, alteration of somatosensory signaling, especially through the cervical muscles via DN, may be more significant than alteration of nociceptive signaling for treatment of CST. This may further help explain why the patient in the present case reported decreased tinnitus symptoms following manual but not electrical needle stimulation.

Interestingly, the patient reported an increase in familiar symptoms related to tinnitus with deeper palpation or DN of the muscles of the cervical spine, including the upper trapezius, splenius capitis, semispinalis capitis, obliquus capitis superior, obliquus capitis inferior, rectus capitis posterior major and rectus capitis posterior minor muscles, which are all innervated by the C1-4 spinal nerves (Bogduk, 1982, 2001; Pu, Tang, and Yang, 2008). Kanold and Young (2001) reported that the C1-8 spinal nerve branches provide somatosensory input to the dorsal cochlear nucleus with the C2

branches being the largest provider. Zhan, Pongstaporn, and Ryugo (2006) also reported on the importance of C2 somatosensory input into the cochlear nucleus. Additionally, these muscles are consistent with many of the muscles identified by Bezerra Rocha, Sanchez, and Tesseroli de Siqueira (2008) as being associated with somatosensory tinnitus.

Furthermore, the specific mechanical action of needle manipulation via twisting may have had a significant effect. The effects of varying techniques of needle manipulation have been examined. Langevin, Churchill, and Cipolla (2001) and Langevin et al. (2001) found that a greater pullout force is required to remove a needle from tissue when the needle is wound in one direction compared to when it is wound in both directions. Moreover, there was a greater pullout force following uni- and bidirectional winding compared to needle insertion without manipulation (Langevin, Churchill, and Cipolla, 2001; Langevin et al., 2001). Importantly, Langevin, Churchill, and Cipolla (2001) noted that, "acupuncture needle rotation (either uni- or bidirectional) may be important to initiate needle grasp, but other types of needle manipulation such as pistoning may also effectively transmit a mechanical signal to cells once needle grasp has been initiated." That is, pistoning in the absence of winding is not justified to elicit mechanotransduction. Consistent with this finding, Zhang, Wang, and McAlonan (2012) found that needle rotation resulted in significantly greater C-fiber stimulation and distal superficial and deep stretch and mechanoreceptor activation compared to lifting, thrusting, scraping, shaking, and flicking.

Prior studies have shown an improvement in ST after physical therapy interventions primarily focused on manual therapy and exercise (Latifpour, Grenner, and Sjudahl, 2009; Michiels et al., 2016; Oostendorp et al., 2016a). While physical therapy has also been found to be effective for CH (Dunning et al., 2016; Jull et al., 2002), the patient in the present report did not report improvements in her headache symptoms following cervical exercises or cervical and/or thoracic manipulation.

Notably, the patient did report a significant improvement in headache symptoms after electrical stimulation was added to DN. Acupuncture with electrical stimulation has been shown to lead to more robust improvements in pain and disability compared to acupuncture with manual stimulation alone in patients with tension-type headaches (Hao, Xue, Dong, and Zheng, 2013) and knee osteoarthritis (Manheimer et al., 2010). Electroacupuncture also seems to have a stronger effect on the regions of the brain responsible for both descriptive and affective pain than manual acupuncture (Napadow et al., 2005). Additionally, dry needling with electrical stimulation has been shown to be superior to

conventional physical therapy in patients with: knee OA (Dunning et al., 2018b); plantar fasciitis, (Dunning et al., 2018a); and tension type headaches (Linde et al., 2009).

The fact that the patient elected to have the SNRB procedure is confounding. However, she underwent the procedure due to financial rather than clinical reasons. Notably, her tinnitus and headache symptoms worsened initially after the SNRB and did not improve again until after continuing with DN treatment. However, the positive effect of the nerve block cannot be ruled out. Despite the patient's history of ineffective nerve blocks, it is possible that the most recent nerve block worked additively with physical therapy to improve the patient's pain and disability related to headaches and tinnitus.

Conclusion

This report describes a patient that showed a significant reduction in symptoms related to cervicogenic somatosensory tinnitus (CST) following physical therapy. Dry needling (DN) with manual stimulation (i.e. winding) in the upper cervical muscles seems to have correlated with a reduction in tinnitus symptoms. The addition of electric stimulation to DN also seems to have improved the patient's headache symptoms. Given that CST and CH often present concurrently, physical therapists must have a strategy for treating both conditions. Further research, including randomized control trials, is required to fully determine the effectiveness of dry needling on this patient population.

Declaration of interest

The authors declare no conflict of interest.

References

- Baguley D, McFerran D, Hall D 2013 Tinnitus. *Lancet* 382: 1600–1607.
- Bezerra Rocha CA, Sanchez TG, Tesseroli de Siqueira JT 2008 Myofascial trigger point: A possible way of modulating tinnitus. *Audiology & Neuro-otology* 13: 153–160.
- Bogduk N 1982 The clinical anatomy of the cervical dorsal rami. *Spine* 7: 319–330.
- Bogduk N 2001 Cervicogenic headache: Anatomic basis and pathophysiologic mechanisms. *Current Pain and Headache Reports* 5: 382–386.
- Boyd-Clark L, Briggs C, Galea M 2002 Muscle spindle distribution, morphology, and density in longus colli and multifidus muscles of the cervical spine. *Spine* 27: 694–701.
- Doi MY, Tano SS, Schultz AR, Borges R, Marchiori LL 2016 Effectiveness of acupuncture therapy as treatment for tinnitus: A randomized controlled trial. *Brazilian Journal of Otorhinolaryngology* 82: 458–465.
- Dunning J, Butts R, Henry N, Mourad F, Brannon A, Rodriguez H, Young I, Arias-Buría JL, Fernández-de-las-Peñas C 2018a Electrical dry needling as an adjunct to exercise, manual therapy and ultrasound for plantar fasciitis: A multi-center randomized clinical trial. *PLoS One* 13: e0205405.
- Dunning J, Butts R, Mourad F, Young I, Fernandez-de-las-Peñas C, Hagins M, Stanislawski T, Donley J, Buck D, Hooks TR, et al. 2016 Upper cervical and upper thoracic manipulation versus mobilization and exercise in patients with cervicogenic headache: A multi-center randomized clinical trial. *BMC Musculoskeletal Disorders* 17: 64.
- Dunning J, Butts R, Mourad F, Young I, Flannagan S, Perreault T 2014 Dry needling: A literature review with implications for clinical practice guidelines. *Physical Therapy Reviews* 19: 252–265.
- Dunning J, Butts R, Young I, Mourad F, Galante V, Bliton P, Tanner M, Fernández-de-las-Peñas C 2018b Periosteal electrical dry needling as an adjunct to exercise and manual therapy for knee osteoarthritis: A multicenter randomized clinical trial. *Clinical Journal of Pain* 34: 1149–1158.
- Farrar JT, Young JP, LaMoreaux L, Werth JL, Poole RM 2001 Clinical importance of changes in chronic pain intensity measured on an 11-point numerical pain rating scale. *Pain* 94: 149–158.
- Hao XA, Xue CC, Dong L, Zheng Z 2013 Factors associated with conflicting findings on acupuncture for tension-type headache: Qualitative and quantitative analyses. *Journal of Alternative and Complementary Medicine* 19: 285–297.
- Ishiyama S, Shibata Y, Ayuzawa S, Matsushita A, Matsumura A 2018 Clinical effect of C2 peripheral nerve field stimulation using electroacupuncture for primary headache. *Neuromodulation* 21: 793–796.
- Jull G, Trott P, Potter H, Zito G, Niere K, Shirley D, Emberson J, Marschner I, Richardson C 2002 A randomized controlled trial of exercise and manipulative therapy for cervicogenic headache. *Spine* 27: 1835–1843.
- Kanold PO, Young ED 2001 Proprioceptive information from the pinna provides somatosensory input to cat dorsal cochlear nucleus. *Journal of Neuroscience* 21: 7848–7858.
- Kulkarni V, Chandy M, Babu K 2001 Quantitative study of muscle spindles in suboccipital muscles of human fetuses. *Neurology India* 49: 355.
- Landgrebe M, Azevedo A, Baguley D, Bauer C, Cacace A, Coelho C, Dornhoffer J, Figueiredo R, Flor H, Hajak G 2012 Methodological aspects of clinical trials in tinnitus: A proposal for an international standard. *Journal of Psychosomatic Research* 73: 112–121.
- Langevin HM, Churchill DL, Cipolla MJ 2001 Mechanical signaling through connective tissue: A mechanism for the therapeutic effect of acupuncture. *FASEB Journal* 15: 2275–2282.
- Langevin HM, Churchill DL, Fox JR, Badger GJ, Garra BS, Krag MH 2001 Biomechanical response to acupuncture needling in humans. *Journal of Applied Physiology* 91: 2471–2478.
- Langguth B, Goodey R, Azevedo A, Bjorne A, Cacace A, Crocetti A, Del Bo L, De Ridder D, Diges I, Elbert T, et al. 2007 Consensus for tinnitus patient assessment and treatment outcome measurement: Tinnitus Research Initiative meeting, Regensburg, July 2006. *Progress in Brain Research* 166: 525–536.

- Latifpour DH, Grenner J, Sjudahl C **2009** The effect of a new treatment based on somatosensory stimulation in a group of patients with somatically related tinnitus. *International Tinnitus Journal* 15: 94–99.
- Levine RA **1999** Somatic (craniocervical) tinnitus and the dorsal cochlear nucleus hypothesis. *American Journal of Otolaryngology* 20: 351–362.
- Levine RA, Oron Y **2015** Tinnitus, handbook of clinical neurology. p. 409–431. Elsevier.
- Linde K, Allais G, Brinkhaus B, Manheimer E, Vickers A, White AR **2009** Acupuncture for tension-type headache. *Cochrane Database of Systematic Reviews* 4: CD007587.
- Liu JX, Thornell LE, Pedrosa-Domellöf F **2003** Muscle spindles in the deep muscles of the human neck: A morphological and immunocytochemical study. *Journal of Histochemistry and Cytochemistry* 51: 175–186.
- Low WK, Rangabashyam MS, Cui SL, Dsouza VD, Ong CS, Teng SW, Li HH **2017** Is electro-acupuncture treatment more effective in somatic tinnitus than in nonsomatic tinnitus? *Medical Acupuncture* 29: 138–144.
- MacDermid JC, Walton DM, Avery S, Blanchard A, Etruw E, McAlpine C, Goldsmith CH **2009** Measurement properties of the neck disability index: A systematic review. *Journal of Orthopaedic and Sports Physical Therapy* 39: 400–417.
- Manheimer E, Cheng K, Linde K, Lao L, Yoo J, Wieland S, van der Windt DA, Berman BM, Bouter LM **2010** Acupuncture for peripheral joint osteoarthritis. *Cochrane Database of Systematic Reviews* 1: CD001977.
- Marks N, Emery P, Onisiphorou C **1984** A controlled trial of acupuncture in tinnitus. *Journal of Laryngology and Otolaryngology* 98: 1103–1109.
- Michiels S, Van de Heyning P, Truijten S, Hallemans A, De Hertogh W **2016** Does multi-modal cervical physical therapy improve tinnitus in patients with cervicogenic somatic tinnitus? *Manual Therapy* 26: 125–131.
- Napadow V, Makris N, Liu J, Kettner N, Kwong K, Hui KK **2005** Effects of electroacupuncture versus manual acupuncture on the human brain as measured by fMRI. *Human Brain Mapping* 24: 193–205.
- Newman CW, Jacobson GP, Spitzer JB **1996** Development of the tinnitus handicap inventory. *Archives of Otolaryngology–Head and Neck Surgery* 122: 143–148.
- Newman CW, Sandridge SA, Jacobson GP **1998** Psychometric adequacy of the Tinnitus Handicap Inventory (THI) for evaluating treatment outcome. *Journal of the American Academy of Audiology* 9: 153–160.
- Okada DM, Onishi ET, Chami FI, Borin A, Cassola N, Guerreiro VM **2006** Acupuncture for tinnitus immediate relief. *Brazilian Journal of Otorhinolaryngology* 72: 182–186.
- Oostendorp RA, Bakker I, Elvers H, Mikolajewska E, Michiels S, De Hertogh W, Samwel H **2016a** Cervicogenic somatosensory tinnitus: An indication for manual therapy plus education? Part 2: A pilot study. *Manual Therapy* 23: 106–113.
- Oostendorp RA, Bakker I, Elvers H, Mikolajewska E, Michiels S, De Hertogh W, Samwel H **2016b** Cervicogenic somatosensory tinnitus: An indication for manual therapy? Part 1: Theoretical concept. *Manual Therapy* 23: 120–123.
- Pu YM, Tang EY, Yang XD **2008** Trapezius muscle innervation from the spinal accessory nerve and branches of the cervical plexus. *International Journal of Oral and Maxillofacial Surgery* 37: 567–572.
- Sanchez TG, Rocha CB **2011** Diagnosis and management of somatosensory tinnitus: Review Article. *Clinics* 66: 1089–1094.
- Shore S, Zhou J, Koehler S **2007** Neural mechanisms underlying somatic tinnitus. *Progress in Brain Research* 166: 107–123.
- Young IA, Dunning J, Butts R, Cleland JA, Fernández-de-las-Peñas C **2019** Psychometric properties of the Numeric Pain Rating Scale and Neck Disability Index in patients with cervicogenic headache. *Cephalalgia* 39: 44–51.
- Zhan X, Pongstaporn T, Ryugo DK **2006** Projections of the second cervical dorsal root ganglion to the cochlear nucleus in rats. *Journal of Comparative Neurology* 496: 335–348.
- Zhang K, Liu Y, Jiang GL **2014** Laws of acupoint selection of prescriptions for treatment of cervicogenic headache by acupuncture: A modern literature research. *Chinese Journal of Integrated Traditional and Western Medicine* 34: 1008–1012.
- Zhang ZJ, Wang XM, McAlonan GM **2012** Neural acupuncture unit: A new concept for interpreting effects and mechanisms of acupuncture. *Evidence-Based Complementary and Alternative Medicine* 2012: 429412.
- Zhou J, Shore S **2004** Projections from the trigeminal nuclear complex to the cochlear nuclei: A retrograde and anterograde tracing study in the guinea pig. *Journal of Neuroscience Research* 78: 901–907.